



## Vitamin D deficiency contributes to development of nasal polyps in Iraqi patients suffering from chronic rhinosinusitis

Mohammed Saeed Abd Ali<sup>1</sup>, Osama Awaad Ali<sup>2\*</sup>

<sup>1</sup> Department of Surgery, College of Medicine, University of Al-Qadisiyah, Iraq.

<sup>2</sup> Department of Surgery, College of Medicine, University of Wasit, Iraq.

\*Corresponding author: Osama Awaad Ali, Department of Surgery, College of Medicine, University of Wasit, Iraq, Email: osamaali@uowasit.edu.iq

Submitted: 10 February 2023; Accepted: 17 March 2023; Published: 14 April 2023

### ABSTRACT

Chronic rhinosinusitis is a disease of the upper respiratory tract of unknown origin, characterized by chronic inflammation of the lining epithelium of nasal and paranasal air sinuses. There are two main phenotypes, chronic rhinosinusitis without polyps and chronic rhinosinusitis with polyps' development. Several reports highlighted the importance of vitamin D in the pathogenesis of chronic rhinosinusitis.

**Aim:** To evaluate vitamin D levels between patients suffering from chronic rhinosinusitis and to explore the relationship between vitamin D deficiency and the severity of chronic rhinosinusitis through radiologic staging score. Also, to determine the role of vitamin D on the development of nasal polyps in Iraqi patients.

**Methods:** Sixty (60) patients with clinical signs and symptoms of chronic rhinosinusitis were recruited at ENT units of Al-Diwaniyah and Al-Kut teaching hospitals in Iraq. Selected individuals were subjected to nasal endoscopy and CT radiographic imaging to assess severity and nasal polyps' formation. Serum samples were also collected to evaluate vitamin D concentration by utilizing quantitative immunofluorescent technique.

**Results:** Serum levels of vitamin D were significantly lower in patients suffering from chronic rhinosinusitis with polyps compared to those who did not present nasal polyps, mean concentration being (17.9±5.9) ng/ml, and (27.3±7.5) ng/ml, respectively, (P<0.001). Correlative analysis and odd ratio estimation presented significant association between vitamin D and nasal polyps' formation (r=-0.578, P<0.001, odd ratio= 51.6%, 95% CL (-11.504 to -4.626). The severity of chronic rhinosinusitis also showed negative correlation with levels of vitamin D, (r=-0.431, P=0.026, odd ratio=14.3%). Furthermore, estimated best cutoff values of vitamin D that can predicts nasal polyps' development in patients with chronic rhinosinusitis was found at 19.95 ng/ml.

**Conclusion:** Patients suffering from chronic rhinosinusitis and polyp growth showed low vitamin D levels compared to those without nasal polyps. Vitamin D deficiency correlated significantly with severity of chronic rhinosinusitis and nasal polyps' formation. The estimated vitamin D cutoff values by the current study could potentially be applied to evaluate the severity of the condition and the risk of nasal polyp growth.

**Keywords:** Vitamin D, nasal polyps, chronic rhinosinusitis

## INTRODUCTION

Chronic rhinosinusitis is a condition of the upper part of the respiratory system which can be recognized as chronic inflammation of the lining epithelium of nasal and paranasal air sinuses (1). The exact etiology of the chronic rhinosinusitis is still to be fully understood (2, 3). The disease can be recognized clinically with signs and symptoms of persistent inflammation of the sinonasal tract for at least twelve weeks of congested nasal cavity with discharge, headache that might be associated with tenderness of the face that can be felt in the nose, eyes, and the forehead, and reduction or complete loss of smell and taste (4, 5). Severe and prolonged inflammation of the sinuses could result in significant radiographic changes on inspection that can be manifested as severely thickened nasal mucosa, complete opacification of the nasal cavity, and modifications in the bony chambers component of the sinuses (6). Nasal endoscopic examination shows that the disease can be recognized into two main phenotypes, chronic rhinosinusitis without polyps and chronic rhinosinusitis with polyps' development (7). Since the factors that can lead to the formation and development of polyps are still poorly understood, several studies indicated a possibility that the observed phenotypes of the disease might be completely independent and could represent different diseases that each have their own unique inflammatory cues (8). However, histopathological findings from studies on the paranasal polyposis that are associated with chronic rhinosinusitis revealed chronic manifestation of the inflammatory response through severe infiltration of immunological cells to the inflammation site, alteration in the basement membrane and the epithelial linings of the paranasal cavity, glandular cells changes, and increased amount of extracellular matrix proteins and condensation of collagen fibers (9).

Studies showed that various forms of infectious agents, environmental factors, and host genetic predisposing factors might play a key role in the pathogenesis of chronic rhinosinusitis (10-12). These factors could be bacterial and fungal infections (13), environmental pollutants and toxins (14), or various types of allergens (15).

Host factors, on the other hand, were mainly observed to control the disease origination and progression via recruiting and concentrating the pro-inflammatory mediators and other immunological responses at the site of inflammation (16).

The crucial role of vitamin D as an anti-inflammatory agent and as immune regulator is well established by several research and clinical studies, as it has been found to regulate most inflammatory mediators and immunological cytokines (17, 18). The potent anti-inflammatory effect of vitamin D is originated from the reported active similarity to the effects of steroidogenic compounds on immune system (19). Vitamin D was reported with direct regulatory effects on several components of the immune system, including monocytes, dendritic cells, T cells, macrophages, cytokines productions, C reactive protein synthesis, tumor necrosis factor alpha, interleukins, and MHC-II molecules (20, 21). Number of observational and epidemiological studies presented a strong correlation between vitamin D deficiency and variety of prevalent chronic conditions such as, diabetes, infertility, cardiac diseases, tumor, and degenerative diseases (22, 23). Vitamin D deficiency has also been reported to regulate pathogenesis of chronic rhinosinusitis and nasal polyps' formation (7, 9, 24).

The current investigation is aimed to explore the relationship between vitamin D deficiency and the severity of chronic rhinosinusitis through radiologic staging score, also to determine the role of vitamin D on the development of nasal polyps in Iraqi patients.

## PATIENTS AND METHODS

The current observational investigation was carried out on 60 adult patients recruited at the time of visit to the ENT units of Al-Diwaniyah and Al-Kut teaching hospitals in Iraq according to the patients' history and clinical manifestation of chronic rhinosinusitis along with the presented findings from nasal endoscopy and CT scans of the paranasal sinuses. Patients' collection, examination, and selection for this study was established in August 2021 and commenced in June 2022. There were forty (40) men and twenty

(20) women, age 18 years and above. All selected individuals were provided with written consent and were informed about the objectives of the study. Patients with signs and symptoms of systemic diseases such as, diabetes, gastrointestinal diseases, cardiac diseases, tumor, or other chronic conditions or medications or pregnancy that could alter immune responses or recent surgical intervention were excluded. Patients on multivitamins supplements were also excluded. All the included patients were subjected to blood vitamin D level evaluation by utilizing Finicare™ vitamin D quantitative test which is based on immunofluorescent technique where the signal intensity was measured by Finicare™ FIA meter (Wondfo Biotech – China). Vitamin D levels  $\leq 20$  ng/ml were considered below the standard range. Severity of chronic rhinosinusitis was assessed by utilizing CT radiographic scores of Lund-Mackay staging system (25), where  $\leq 12$  points were considered not severe. Statistical analysis, patients' information was collected on Microsoft Excel 365 software. Data were processed for statistical evaluation and correlation estimation of vitamin D with nasal polyps were obtained by the Statistical package SPSS software-version 26 (IBM, USA). Linear regression analysis was performed to examine the relationship between vitamin D and Lund-Mackay score, and receiver operator characteristic (ROC) curve was applied for estimating the best cutoff values of vitamin D that predicts nasal polyps' development and severity of chronic rhinosinusitis.  $P \leq 0.05$  was considered significant.

## RESULTS

According to the findings from nasal endoscopy, patients with chronic rhinosinusitis were classified according to clinical manifestation of nasal polyp's formation in the paranasal air sinuses into, 35(58.3%) patients suffering from chronic rhinosinusitis with nasal polyps, and 25(41.7%) patients did not present nasal polyps. Demographic evaluation showed majority of those patients with nasal polyps were males 25(71.4%), compared to 10(28.6%) females. However, no significant differences were observed between the two groups according to sex of the participants, ( $P=0.258$ ). Similarly, age

did not present significant variance between those patients who developed nasal polyps and others who did not, being ( $41.2 \pm 8.3$ ) years and ( $38.0 \pm 11.4$ ) years, respectively, ( $P=0.226$ ). Investigating patients' distribution into age groups displayed significant variance ( $P=0.025$ ), where the highest proportion of patients with nasal polyps found at the age range of late adult of 41-50 years (15(42.9%)), compared to those with only chronic rhinosinusitis being the highest proportion reported at a much younger age group of 20-30 years (11(44.0%)). Symptom duration of chronic rhinosinusitis and the suffering from the disease were not significantly variants between these groups ( $P=0.374$ ), as results indicated to some degree that both groups were equally affected by the disease for the given durations. A significantly high proportion of patients with nasal polyps were reported with history of tobacco smoking 22(62.9%), whereas a relatively smaller number of cases were non-smokers 13(37.1%). A significant difference was witnessed in this part of the study between groups, ( $P=0.003$ ). Similarly, patients' history with seasonal allergy was also observed to correlate with nasal polyps' development, ( $P=0.002$ ). Allergic rhinitis was documented in 31(51.6%) of the total included patients with chronic rhinosinusitis.

Evaluating serum vitamin D in patients with chronic rhinosinusitis presented a very interesting finding. The highest proportion of patients with vitamin D deficiency ( $\leq 20$  ng/ml) was reported in patients with nasal polyps 27(77.1%) compared to 21(84.0%) patients who did not present nasal polyps and their vitamin D level was found within the normal range, figure 1. A highly significant variance between the mean concentrations of vitamin D was observed between the groups ( $P < 0.001$ ), being ( $17.9 \pm 5.9$ ) ng/ml in the group that presented chronic rhinosinusitis with nasal polyps' formation, and ( $27.3 \pm 7.5$ ) ng/ml of without polyps. Correlative analysis and odd ratio estimation have also revealed significant association between vitamin D and nasal polyps' formation ( $r = -0.578$ ,  $P < 0.001$ , odd ratio = 51.6%, 95% CL (-11.504 to -4.626). The severity of the disease which is based on CT radiographic scores of Lund-Mackay staging has showed negative correlation

with levels of vitamin D, where low level of vitamin D was associated significantly with high Lund-Mackay score (P=0.026, odd ratio=14.3%), table 2, figure 2. Thus, the severity of chronic rhinosinusitis and the tendency to develop polyps were both evidently linked and affected by serum vitamin D concentration, and the severity of chronic rhinosinusitis was less prominent in

patients with normal range of vitamin D. The estimated best cutoff values of vitamin D that can predicts nasal polyps' development in patients with chronic rhinosinusitis was found at 19.95 ng/ml, with evident proximity to the normal range of vitamin D, (AUC: 83.5±0.05, P<0.001, 95%CI (0.734 – 0.937), sensitivity 84.0%, 1-specificity 22.9%), figure 3.

**TABLE 1:** Patients' demographic characteristics classified according to nasal polyps' growth

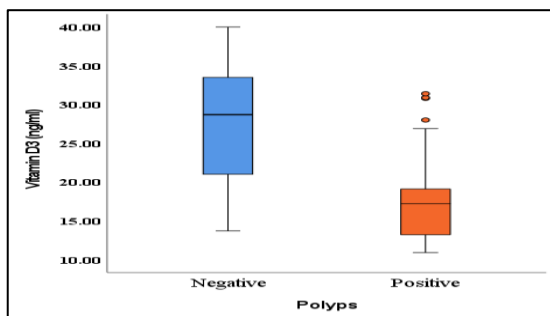
Patients' characteristics	Chronic rhinosinusitis with nasal polyps	Chronic rhinosinusitis without nasal polyps	P value
Number of patients (%)	35(58.3)	25(41.7)	
Male	25(71.4%)	15(60.0%)	0.258
Female	10(28.6%)	10(40.0%)	
Age (years)	41.2±8.3	38.0±11.4	0.226
Age groups (years)			
20-30	5(14.3%)	11(44.0%)	0.025*
31-40	11(31.4%)	3(12.0%)	
41-50	15(42.9%)	6(24.0%)	
≥51	4(11.4 %)	5(20.0%)	
Symptoms duration			
4 - 8 months	16(45.7%)	13(52.0%)	0.374
8-12 months	11(31.4%)	4(16.0%)	
≥12 months	8(22.9%)	8(32.0%)	
Smoking			
Non-smokers	13(37.1%)	19(76.0%)	0.003*
Smokers	22(62.9%)	6(24.0%)	
Vitamin D3			
Mean±SD (ng/ml)	17.9±5.9	27.3±7.5	<0.001*
≤20 ng/ml	27(77.1%)	4(16.0%)	<0.001*
≥20 ng/ml	8(22.9%)	21(84.0%)	
History of seasonal allergic rhinitis			
Yes	24(68.6%)	7(28.0%)	0.002*
No	11(31.4%)	18(72.0%)	
Lund-Mackay score			
Mean±SD	12.83±6.2	8.20±5.3	0.004*
0-12 points	18(51.4%)	20(80.0%)	0.022*
13-24 points	17(48.6%)	5(20.0%)	

\*Significant difference (P≤0.05).

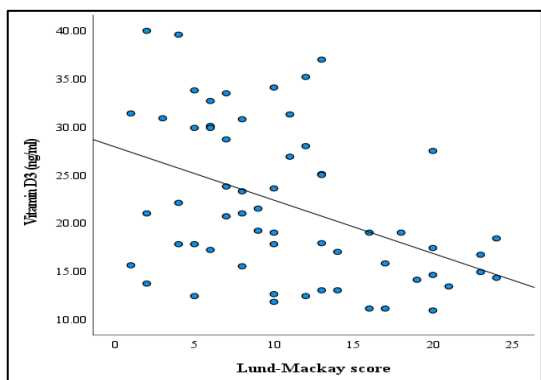
**TABLE 2:** Correlative analysis and odd ratio estimate of serum vitamin D3 level to development of nasal polyps, and Lund-Mackay score.

	Correlation coefficient (r)	P value	Odd ratio	95% CI
Development of nasal polyps	-0.578	<0.001*	-0.516	-11.504 - -4.626
Lund-Mackay score	-0.431	0.026*	0.143	-0.613 - -0.041

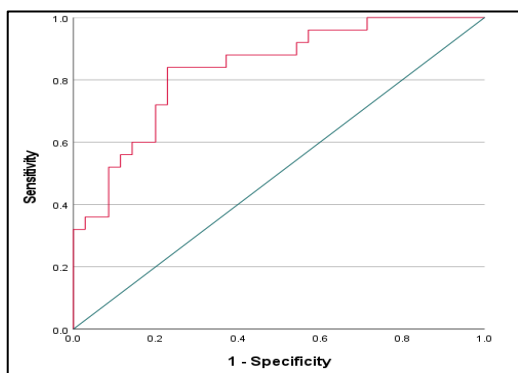
\*Significant association



**FIGURE 1:** Serum vitamin D3 level according to patients with nasal polyps.



**FIGURE 2:** Relationship between serum level of vitamin D (ng/ml) and Lund-Mackay score.



**FIGURE 3:** Receiver operator characteristic (ROC) curve estimate the best cutoff values of vitamin D3 that predicts nasal polyps' development in patients with chronic rhinosinusitis.

### DISCUSSION

The current understanding regarding the pathogenesis of chronic rhinosinusitis and the observed tendency to develop paranasal polyps is still limited. This calls for extensive research as well as additional clinical investigations in order to uncover the negative impact that chronic rhinosinusitis has on both general health and

quality of life. (2, 3, 26). However, this study undoubtedly showed a significant inverse correlation between serum levels of vitamin D and the severity of chronic rhinosinusitis. It was also observed that patients who suffered from vitamin D deficiency had a higher risk of developing paranasal polyps which are seen to be associated with the clinical manifestation of chronic rhinosinusitis. The nasal polyps were detected in 51.6% of the patients who were identified with vitamin D deficiency.

The importance of vitamin D in such circumstances come from the proposed role as a potent anti-inflammatory and an effective regulator of the immune system responses that which govern most of the cellular responses to various forms of inflammatory reactions (17-19, 27). Studies showed substantial effects of vitamin D on recruiting and concentrating immunological components at the inflammation site such as, monocytes, T cells, complementary system, eosinophils, macrophages, interleukins, and various types of cytokines (7, 28, 29). The extensively documented similarity of vitamin D to the pathophysiological activity of corticosteroids has been suggested to address many medical conditions that is similar in characteristics to chronic rhinosinusitis (30, 31). Indeed, studies showed that vitamin D could effectively relief signs and symptoms of asthma, allergic rhinitis, and atopic dermatitis (32-34). Studies also highlighted the significant impact of vitamin D on boosting the innate immunity of children, thus prevent child suffering from asthma, and allergic rhinitis (35, 36).

It has been suggested that seasonal atopy may play a larger impact on triggering and progression of chronic rhinosinusitis than is currently understood(37). Nevertheless, a relatively large proportion of the participants with nasal polyps (68.6%) who were also reported with low level vitamin D are presented to this study with history of seasonal allergic rhinitis. It could be hypothesized that such patients tend to avoid outdoors activities during the summer sunny days in order to reduce exposure to airborne allergens, like pollens and other irritants, which in turn may have impacted levels of vitamin D found in their bodies. In such cases, vitamin D deficiency might induce



abnormal allergic responses that could potentially induce further damage to the sinuses mucosa and create predisposing factors that might contribute to the development of paranasal polyps(1).

The current data would strongly indicate that there is a correlating detrimental influence of vitamin D deficiency on the health of the sinus mucosa. Indeed, various studies showed that vitamin D was found to negatively related to the likelihood of acquiring various forms of sinus infections and to triggering development of paranasal polyps (1, 7, 9, 21, 38-40). Lower vitamin D levels were linked to a decrease in the active form of vitamin D metabolite (25-hydroxyvitamin D), and an increase in dendritic cells in the sinus mucosa of patients with nasal polyps(40-42). Moreover, analogues compounds of vitamin D (calcitriol and tacalcitol) yielded a significant suppressing effect on the rate of cellular proliferation and expression of interleukins 6 and 8 when examined on cultured fibroblast cells derived from the mucosal lining of patients with nasal polyps (43, 44). Vitamin D supplementation reduces severity of mucosal eosinophilic infiltration to the nasal polyps and enhanced corticosteroid effects in patients with severe chronic rhinosinusitis and recurrence of nasal polyps (29, 45, 46).

Lund-Mackay staging score which is based CT radiographic findings clearly showed a damaging effect of vitamin D deficiency on the health of the mucosal lining of the nasal sinuses and on the severity of the chronic rhinosinusitis. Similar observations were made by previous studies linked vitamin D deficiency to sinus bone remodeling on CT in comparison to patients with sufficient vitamin D serum levels (9, 41, 47). A positive relationship was found between vitamin D and severity scoring which has been established by many studies, including the severity and grades of polyp's development (9, 48).

Given central role of vitamin D as the anti-inflammatory and the reported activity in

modulating innate and adaptive immunity of the nasal mucosa and based on the current findings, it seems that persistent chronic infection of the paranasal sinus without providing adequate

dietary vitamin D may induce depletion of the endogenous levels of vitamin D as what has been observed in patients with severe manifestations of chronic rhinosinusitis and nasal polyps formation.

Hence, it is suggested by the current investigation that patients who did not show nasal polyps at the time of examination and presented with low vitamin D are to some degree be at risk of developing nasal polyps with further progression of chronic rhinosinusitis, if left untreated. The postulated outcome therefore recommends providing adjunct therapy with vitamin D supplementation as part of the follow-up procedure. Vitamin D supplementation could provide an efficient and risk-free supplementary therapeutic method for treating patients with chronic rhinosinusitis and help to halt the disease's progression to more severe versions of the condition. It could also provide an effective therapeutic method that can complement both surgical and conventional therapies, hence enhancing the overall clinical outcome for patients.

## CONCLUSION

The current investigation showed that vitamin D levels were found considerably lower in patients suffering from chronic rhinosinusitis and polyp growth compared to those without nasal polyps. The study also revealed a significant correlation between vitamin D and disease severity in CT radiographic findings. It is suggested therefore that serum vitamin D levels could be included in every standard evaluation and treatment protocol of patients with chronic rhinosinusitis. The estimated vitamin D cutoff values by the current study could potentially be utilized to help evaluate the severity of the condition and the risk of nasal polyp growth.

## CONFLICT OF INTEREST

The authors declare no conflict of interest.

## REFERENCES

1. Bavi F, Movahed R, Salehi M, Hossaini S, Bakhshae M. Chronic rhinosinusitis with

- polyposis and serum vitamin D levels. *Acta Otorhinolaryngol Ital.* 2019;39(5):336-40.
2. Stevens WW, Lee RJ, Schleimer RP, Cohen NA. Chronic rhinosinusitis pathogenesis. *J Allergy Clin Immunol.* 2015;136(6):1442-53.
  3. van Drunen CM, Mjösberg JM, Segboer CL, Cornet ME, Fokkens WJ. Role of Innate Immunity in the Pathogenesis of Chronic Rhinosinusitis: Progress and New Avenues. *Current Allergy and Asthma Reports.* 2012;12(2):120-6.
  4. DeConde AS, Mace JC, Alt JA, Soler ZM, Orlandi RR, Smith TL. Investigation of change in cardinal symptoms of chronic rhinosinusitis after surgical or ongoing medical management. *Int Forum Allergy Rhinol.* 2015;5(1):36-45.
  5. Kern RC, Conley DB, Walsh W, Chandra R, Kato A, Tripathi-Peters A, et al. Perspectives on the etiology of chronic rhinosinusitis: an immune barrier hypothesis. *Am J Rhinol.* 2008;22(6):549-59.
  6. Rathor A, Bhattacharjee A. Clinical-radiological correlation and role of computed tomography staging in chronic rhinosinusitis. *World J Otorhinolaryngol Head Neck Surg.* 2017;3(3):169-75.
  7. Wang F, Yang Y, Chen H. Vitamin D deficiency are associated with subjective disease severity in Chinese patients with chronic rhinosinusitis with nasal polyps. *Am J Otolaryngol.* 2019;40(1):36-9.
  8. Lam K, Schleimer R, Kern RC. The Etiology and Pathogenesis of Chronic Rhinosinusitis: a Review of Current Hypotheses. *Curr Allergy Asthma Rep.* 2015;15(7):41.
  9. Wang L-F, Lee C-H, Chien C-Y, Chen JY-F, Chiang F-Y, Tai C-F. Serum 25-hydroxyvitamin D Levels are Lower in Chronic Rhinosinusitis with Nasal Polyposis and are Correlated with Disease Severity in Taiwanese Patients. *American Journal of Rhinology & Allergy.* 2013;27(6):e162-e5.
  10. Bose S, Grammer LC, Peters AT. Infectious Chronic Rhinosinusitis. *J Allergy Clin Immunol Pract.* 2016;4(4):584-9.
  11. Kato A, Schleimer RP, Bleier BS. Mechanisms and pathogenesis of chronic rhinosinusitis. *J Allergy Clin Immunol.* 2022;149(5):1491-503.
  12. Levchenko AS, Piskunov VS, Konoplya NA, Bushueva OY, Raspopov AA, Mezentseva OY, et al. Genetic Aspects of Chronic Rhinosinusitis. *Russian Journal of Genetics.* 2018;54(8):910-8.
  13. Piromchai P, Thanaviratnanich S. Invasive Fungal Rhinosinusitis versus Bacterial Rhinosinusitis with Orbital Complications: A Case-Control Study. *The Scientific World Journal.* 2013;2013:453297.
  14. Sundaresan AS, Hirsch AG, Storm M, Tan BK, Kennedy TL, Greene JS, et al. Occupational and environmental risk factors for chronic rhinosinusitis: a systematic review. *Int Forum Allergy Rhinol.* 2015;5(11):996-1003.
  15. Baroody FM, Mucha SM, deTineo M, Naclerio RM. Evidence of maxillary sinus inflammation in seasonal allergic rhinitis. *Otolaryngol Head Neck Surg.* 2012;146(6):880-6.
  16. Hulse KE. Immune Mechanisms of Chronic Rhinosinusitis. *Curr Allergy Asthma Rep.* 2016;16(1):1.
  17. Krajewska M, Witkowska-Sędek E, Rumińska M, Stelmaszczyk-Emmel A, Sobol M, Majcher A, et al. Vitamin D Effects on Selected Anti-Inflammatory and Pro-Inflammatory Markers of Obesity-Related Chronic Inflammation. *Frontiers in Endocrinology.* 2022;13.
  18. Yin K, Agrawal DK. Vitamin D and inflammatory diseases. *J Inflamm Res.* 2014;7:69-87.
  19. Sansoni ER, Sautter NB, Mace JC, Smith TL, Yawn JR, Lawrence LA, et al. Vitamin D3 as a novel regulator of basic fibroblast growth factor in chronic rhinosinusitis with nasal polyposis. *Int Forum Allergy Rhinol.* 2015;5(3):191-6.
  20. Guillot X, Semerano L, Saidenberg-Kermanac'h N, Falgarone G, Boissier MC. Vitamin D and inflammation. *Joint Bone Spine.* 2010;77(6):552-7.
  21. Li B, Wang M, Zhou L, Wen Q, Zou J. Association between serum vitamin D and chronic rhinosinusitis: a meta-analysis. *Braz J Otorhinolaryngol.* 2021;87(2):178-87.
  22. Wang H, Chen W, Li D, Yin X, Zhang X, Olsen N, et al. Vitamin D and Chronic Diseases. *Aging Dis.* 2017;8(3):346-53.
  23. Janjusevic M, Gagno G, Fluca AL, Padoan L, Beltrami AP, Sinagra G, et al. The peculiar role of vitamin D in the pathophysiology of cardiovascular and neurodegenerative diseases. *Life Sciences.* 2022;289:120193.
  24. Zand V, Baradaranfar M, Vaziribozorg S, Mandegari M, Mansourimanesh M, Saeidieslami N. Correlation of Serum Vitamin D Levels with Chronic Rhinosinusitis Disease Severity. *Iran J Otorhinolaryngol.* 2020;32(108):35-41.
  25. Bhattacharyya N, Jones DT, Hill M, Shapiro NL. The Diagnostic Accuracy of Computed Tomography in Pediatric Chronic Rhinosinusitis. *Archives of Otolaryngology-Head & Neck Surgery.* 2004;130(9):1029-32.
  26. Bequignon E, Mangin D, Bécaud J, Pasquier J, Angely C, Bottier M, et al. Pathogenesis of

- chronic rhinosinusitis with nasal polyps: role of IL-6 in airway epithelial cell dysfunction. *Journal of Translational Medicine*. 2020;18(1):136.
27. Shahangian A, Schlosser RJ. Role of Vitamin D in Pathogenesis of Chronic Sinusitis with Nasal Polyposis. *Adv Otorhinolaryngol*. 2016;79:86-90.
  28. Ao T, Kikuta J, Ishii M. The Effects of Vitamin D on Immune System and Inflammatory Diseases. *Biomolecules*. 2021;11(11).
  29. de Groot JC, van Roon EN, Storm H, Veeger NJ, Zwinderman AH, Hiemstra PS, et al. Vitamin D reduces eosinophilic airway inflammation in nonatopic asthma. *J Allergy Clin Immunol*. 2015;135(3):670-5.e3.
  30. Mehta AA, Agrawal AD, Appanna V, Chaudagar KK. Vitamin D improves corticosteroid efficacy and attenuates its side-effects in an animal model of asthma. *Can J Physiol Pharmacol*. 2015;93(1):53-61.
  31. Cutolo M, Paolino S, Sulli A, Smith V, Pizzorni C, Seriola B. Vitamin D, steroid hormones, and autoimmunity. *Ann N Y Acad Sci*. 2014;1317:39-46.
  32. Mansour NO, Mohamed AA, Hussein M, Eldemiry E, Daifalla A, Hassanin S, et al. The impact of vitamin D supplementation as an adjuvant therapy on clinical outcomes in patients with severe atopic dermatitis: A randomized controlled trial. *Pharmacology Research & Perspectives*. 2020;8(6):e00679.
  33. Freishtat RJ, Iqbal SF, Pillai DK, Klein CJ, Ryan LM, Benton AS, et al. High prevalence of vitamin D deficiency among inner-city African American youth with asthma in Washington, DC. *J Pediatr*. 2010;156(6):948-52.
  34. Tian HQ, Cheng L. The role of vitamin D in allergic rhinitis. *Asia Pac Allergy*. 2017;7(2):65-73.
  35. Erkkola M, Kaila M, Nwaru BI, Kronberg-Kippilä C, Ahonen S, Nevalainen J, et al. Maternal vitamin D intake during pregnancy is inversely associated with asthma and allergic rhinitis in 5-year-old children. *Clin Exp Allergy*. 2009;39(6):875-82.
  36. Bener A, Ehlayel MS, Bener HZ, Hamid Q. The impact of Vitamin D deficiency on asthma, allergic rhinitis and wheezing in children: An emerging public health problem. *J Family Community Med*. 2014;21(3):154-61.
  37. Marcus S, DelGaudio JM, Roland LT, Wise SK. Chronic Rhinosinusitis: Does Allergy Play a Role? *Medical Sciences*. 2019;7(2):30.
  38. Kalińczak-Górna P, Radajewski K, Burduk P. Relationship between the Severity of Inflammatory Changes in Chronic Sinusitis and the Level of Vitamin D before and after the FESS Procedure. *J Clin Med*. 2021;10(13).
  39. Mostafa Bel D, Taha MS, Abdel Hamid T, Omran A, Lotfi N. Evaluation of vitamin D levels in allergic fungal sinusitis, chronic rhinosinusitis, and chronic rhinosinusitis with polyposis. *Int Forum Allergy Rhinol*. 2016;6(2):185-90.
  40. Mulligan JK, Pasquini WN, Carroll WW, Williamson T, Reaves N, Patel KJ, et al. Dietary vitamin D3 deficiency exacerbates sinonasal inflammation and alters local 25(OH)D3 metabolism. *PLoS One*. 2017;12(10):e0186374.
  41. Mulligan JK, White DR, Wang EW, Sansoni SR, Moses H, Yawn RJ, et al. Vitamin D3 deficiency increases sinus mucosa dendritic cells in pediatric chronic rhinosinusitis with nasal polyps. *Otolaryngol Head Neck Surg*. 2012;147(4):773-81.
  42. Mulligan JK, Nagel W, O'Connell BP, Wentzel J, Atkinson C, Schlosser RJ. Cigarette smoke exposure is associated with vitamin D3 deficiencies in patients with chronic rhinosinusitis. *J Allergy Clin Immunol*. 2014;134(2):342-9.
  43. Rostkowska-Nadolska B, Kuśmierz D, Kapral M, Latocha M, Swiatkowska L, Fraczek M. [The change of proliferative potential of fibroblasts derived of nasal polyps in vitro cultured, influenced by derivatives vitamins D]. *Otolaryngol Pol*. 2007;61(5):661-7.
  44. Rostkowska-Nadolska B, Sliupkas-Dyrda E, Potyka J, Kusmierz D, Fraczek M, Krecicki T, et al. Vitamin D derivatives: calcitriol and tacalcitol inhibits interleukin-6 and interleukin-8 expression in human nasal polyp fibroblast cultures. *Adv Med Sci*. 2010;55(1):86-92.
  45. Murdaca G, Paladin F, Gangemi S. Role of Vitamin D in the Clinical Course of Nasal Polyposis. *Biomedicines*. 2021;9(8):855.
  46. Hashemian F, Sadegh S, Jahanshahi J, Seif Rabiei MA, Hashemian F. Effects of Vitamin D Supplementation on Recurrence of Nasal Polyposis after Endoscopic Sinus Surgery. *Iran J Otorhinolaryngol*. 2020;32(108):21-8.
  47. Schlosser RJ, Soler ZM, Schmedes GW, Storck K, Mulligan JK. Impact of vitamin D deficiency upon clinical presentation in nasal polyposis. *Int Forum Allergy Rhinol*. 2014;4(3):196-9.
  48. Stokes PJ, Rimmer J. The Relationship between Serum Vitamin D and Chronic Rhinosinusitis: A Systematic Review. *American Journal of Rhinology & Allergy*. 2016;30(1):23-8.