



The effect of warfarin on skeleton development of fetuses' rats

Rana. K. Abdulsamad¹, Faris S. Kata¹, Alaa A. Sawad^{2*}

¹Department of Biology, College of Education for Pure Science, University of Basrah, Basrah, Iraq.

²Department of Anatomy, College of Veterinary Medicine, University of Basrah, Basrah, Iraq.

*Corresponding author: Alaa A. Sawad, Department of Anatomy, College of Veterinary Medicine, University of Basrah, Basrah, Iraq, Email: alaasawad24@gmail.com

Submitted: 18 February 2023; Accepted: 17 March 2023; Published: 03 April 2023

ABSTRACT

The pregnancy period is characterized by the critical time of the pregnant mother's exposure to external impacts, which are most severe during the so-called embryonic period. The study aimed toward study the effects of warfarin in the developing rat fetus. Three-month adult virgin female Wistar albino rats (*Rattus norvegicus*) were used. They are Left to adapt for one week and then isolated with males by two females with one male for mating determined the zero-gestation day. Pregnant females were arbitrarily divided into three equals with eight rats for each. The first group is control kept without any treatment The second and third groups take 0.1 or 0.05 mg/kg B.t of warfarin respectively, daily from (zero - 15th) day of gestation. The Collection of the blood samples from heart of pregnant rats for biochemical study via using Kit of ELISA technique to estimation the concentration of Osteocalcin and matrix Gla protein. The pregnant animals were sacrificed at (16th) day of gestation The fetuses' specimens were collected for histological processing. Major anomalies were observed on incomplete ossification of the hind leg and wavy ribs by using double stained Alizarine red and Alcian blue. The histological examination of the vertebral column in the group of treated fetuses reveals degeneration at the vertebrae, damage to the intervertebral tissue, hemorrhage and necrosis. They are a significant decrease in the Matrix Gla protein and Osteocalcin in serum of pregnant rats.

Keywords: *Warfarin, osteocalcin, MGP, skeletal abnormalities*

INTRODUCTION

The anticoagulant rodenticides are a substance that prevent the vitamin K-dependent steps in the coagulation cascade in the liver, like warfarin, causing hemorrhage and death by interfering with normal blood clotting, the first-generation materials are not sufficiently toxic to reason death after a single nourishing while the Second products have a better affinity to binding the places in the vertebrate, liver and consequently show greater accumulation and perseverance in the body 1. The contact to the low levels of anticoagulants may pathological or

behavioral effects, in most cases the animals appeared weak, have a movement with a slow reaction and more susceptible to the infection or accidents, the second-generation anticoagulants have a higher potency than first-generation anticoagulants is related to accumulation and slow elimination from the body after absorption, the anticoagulants accumulate in the liver which is the target organ for their action². The warfarin is the most widely used as oral anticoagulant (OAC) in worldwide for the prevention of thromboembolic events in the great risk patients a heart attack³.

Previous studies revealed that the patient who attempted a suicide while taking a high dose of warfarin was successfully treated with blood transfusion and vitamin K injection without any complications. Currently, 0.5–1.5% of the world's population receives the medication on an annual basis 4. The Osteocalcin is the most abundant non-collagenous protein that is found in the bone and is comprised of 49 amino acids (AA) 5. Hauschka discovered Osteocalcin in bone, it has a highly conserved sequence among the vertebrates and binding with calcium to form hydroxyapatite crystals 6. The matrix Gla protein (MGP) consist of 84 amino acid residues. it belongs part of the vitamin K-dependent Gla protein family, it's a small, highly conserved protein and produced predominantly by chondrocytes and vascular smooth muscle cells. The matrix Gla protein was recognized the first time in 1983 in bovine bone through Price and co-workers. it was the second Gla protein isolated from bone and demonstrated strongly associated with the collagenous bone matrix 7. The osteocalcin and matrix Gla protein biomarkers can give us a guide to examination pathological change which effect on the bone's development 8. The study has given a new insight of the effect of warfarin on the level of osteocalcin and MGP and in serum of pregnant mothers that treated by warfarin during a gestation and effect of fetuses' development.

MATERIALS AND METHODS

Three-month adult virgin female Wistar albino rats (*Rattus norvegicus*) were used. The average weighing is about (275 ± 25) g they were bred in the college's animal house Veterinary Medicine Universities of Basrah. These females were scanned periodically by the vaginal smear technique, to ensure that they were always in regular estrous. They are Left to adapt for one week and then isolated with males by two females with one male for mating determined the zero-gestation day 9. Pregnant females were arbitrarily divided into three equals with eight rats for each. The first group is control kept without any treatment The second and third groups take 0.1 or 0.05 mg/kg B. of warfarin

respectively, daily from (zero - 15th) day of gestation (organogenesis period). Depending on the half-lethal dose of warfarin (58 mg /kg) 10. The two different doses of Warfarin (low and high): were made. The pregnant animals were sacrificed at (16th) day of gestation under general anesthesia of a mixture of Xylazine (90 mg/kg) and Ketamine (10 mg/kg) 11, The Collection of the blood sample from heart of pregnant rats were placed in a covered gel tube then, the gel tube centrifuged at 3,000 rpm for 10 minutes 12. The serum directly transferred into Eppendorf tube till it was used in a biochemical study via using Kit of ELISA technique to estimation the concentration of Osteocalcin and matrix Gla protein (Depending on the manufacturer instructions, USA Al-Shkairate institution). The fetuses' specimens were directly place in neutral buffered formalin fixative (10%) for (24-48) hrs. for histological processing. The tissues section was stained with eosin and hematoxylin 13. The double staining technique proposed by Kimmel and Trammel, the skin of fetuses was removed and fetuses' specimens were directly put for at least 24 hr. in the acid staining solution (pH 5 2.8) at room temperature and then dehydrated in 96% of ethanol for at least 6 hrs. Soaking of soft tissues was performed by putting specimens in the basic staining solution for 30 hrs. at room temperature, whereas renewing the solution at least three times. Clearing and hardening was performed by placing specimens in the cleaning solution for at least 8 hr. keeping of double-stained fetuses was performed in a 1:1 ethanol 70% and glycerin mixture 14.

Statistical analysis

Data were given as mean \pm standard error of the mean. The litter was regarded as the experimental unit of comparison for all group, effects of warfarin on fetal growth and effected MGP and Osteocalcin in serum of pregnant rats were determined by one way ANOVA.

RESULTS

Double Staining (Whole mount)

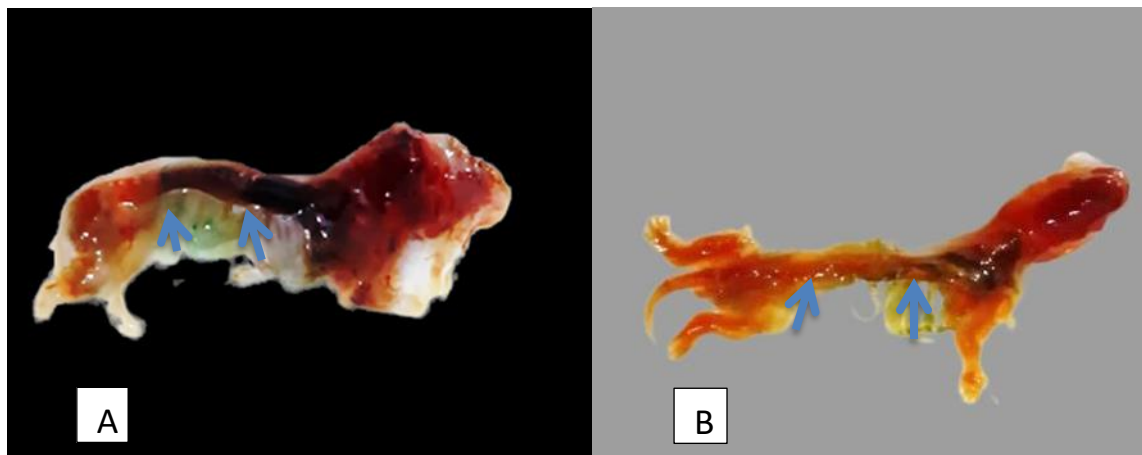


FIG 1: photomicrography of two rat fetuses (16th day) of gestation, (B) is control, (A) fetus obtained from rat treated orally with high dose of warfarin 0.1/kg b. wt. during the organogenesis period showing incomplete ossification of hind limb and wavy ribs.

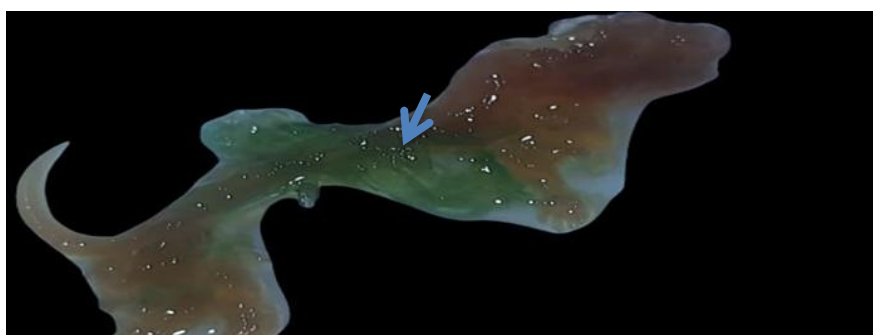


FIGURE 2: fetus obtained from a rat treated orally with warfarin 0.01mg/kg b. wt. during the organogenesis period showing the areas without ossification and no stained cartilage

Microscopic study of histopathological changes of fetus

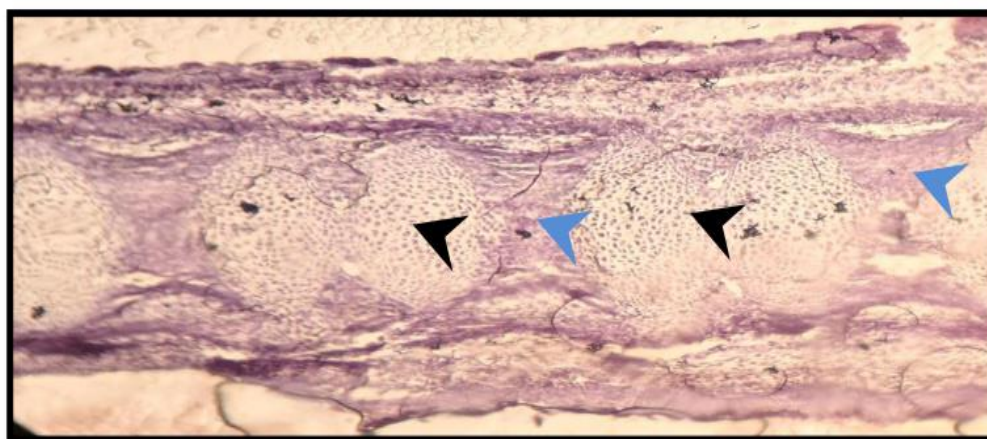


FIG 3: photomicrography of vertebra column of fetus 16th days age of control group shows normal vertebral structure (black arrow), normal intervertebral tissue (blue arrow) H&E 125X

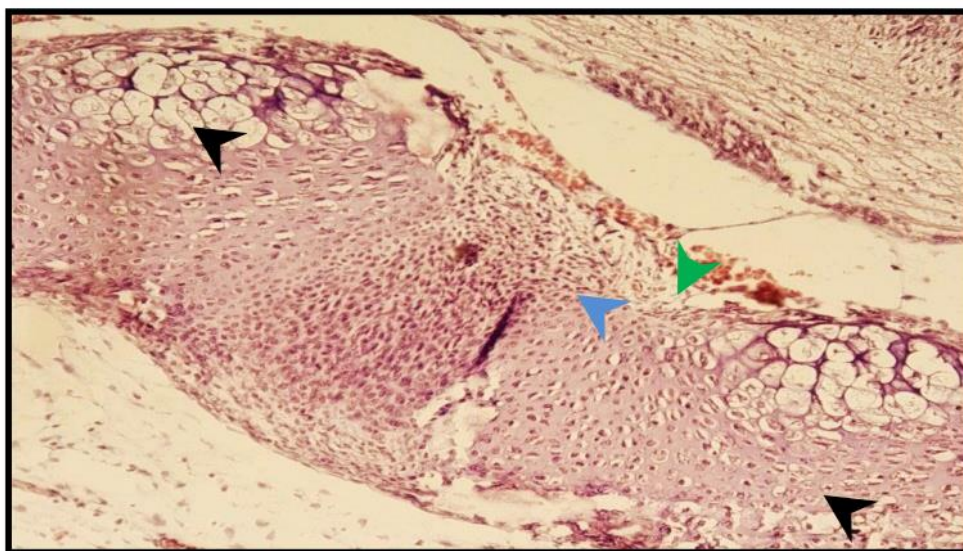


FIG 4: photomicrography of vertebral column of fetus (16th day) of warfarin treated group shows moderate degeneration of the vertebrae (black arrow) damage of the intervertebral tissue (blue arrow) and hemorrhage (green arrow) H&E 125X

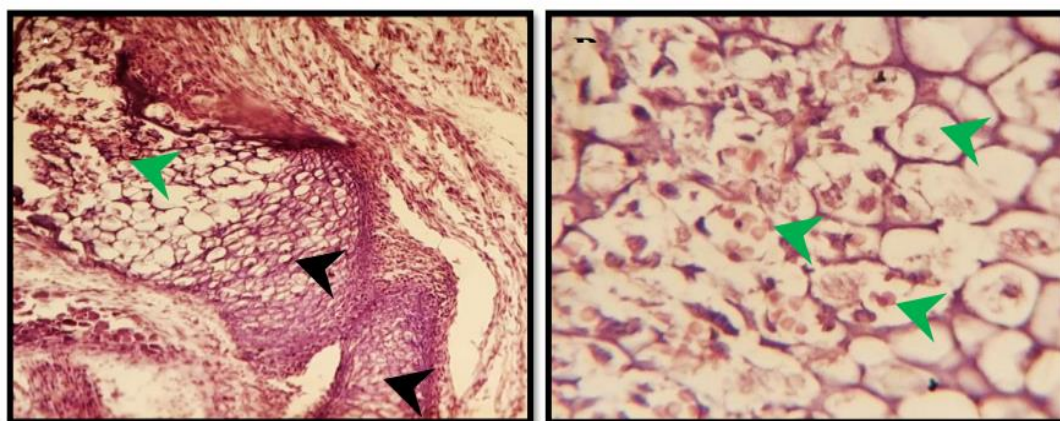


FIG 5: photomicrography of vertebral column of fetus 16th days age treated with high dose warfarin shows marked degeneration (back arrow) and Necrosis (green arrow) of the vertebrae H&E A) 125X B)500X

Estimation of biomarker Osteocalcin in the serum of pregnant rats treated with warfarin

TABLE 1: The mean value of Osteocalcin at 16 days of gestation.

Name of group	Mean± S.D of Osteocalcin (16 day)/(pg/ml) N=8
Control	8.64a ± 0.71
Low Dose(0.05mg/kg)	7.35b± 0.45
High Dose(0.1mg/kg)	7.60b ± 0.33

The small letter (a, b) refers to significant value at level of $P \leq 0.05$.

TABLE 2: The mean value of Matrix Gla protein at 16 days of gestation.

Name of group	Mean± S.D of MGP (16 day)/(pg/ml) n=8
Control	1.07a ± 0.12
Low Dose (0.05mg/kg)	0.40b ± 0.40
High Dose (0.1mg/kg)	0.42b ± 0.42

The small letter (a) refers to significant value at level of $P \leq 0.05$

DISCUSSION

This study demonstrated the congenital malformations and teratogenicity of the warfarin in the fetuses obtained from a mother treated orally with warfarin through the organogenesis period show large incomplete ossification of the skull, large opened fontanel, sacral and coccygeal vertebrae, metatarsal bones, coccygeal and sacral vertebrae, incomplete ossification of hind limb and wavy ribs these results agree with Finkelstein et al¹⁵. These changes occur because of warfarin may be impaired formation synthesis of proteins crucial for bone and cartilage in fetal which result warfarin embryopathy¹⁶. A number of fetuses show areas without ossification and no stained cartilage, while other show is as stained with blue indicate cartilage formation. The results transverse section in the skull of rat fetuses, obtained from treated group of warfarin 0.1mg/kg B. Wt. through the organogenesis period time noticed no calcification happen and incomplete development of bone and the Importance of Half-life described the congenital anomalies after exposure to the warfarin in human include congenital anomalies in bones and hemorrhage complications, these changes occur due to warfarin may be impaired the synthesis of proteins important for bones and cartilage in the fetal¹⁷. The vertebral column of the fetus on the (16 day) of gestation in control group noticed normal vertebral structure and normal intervertebral tissue, Whereas the sections of vertebral column of fetus which treated with the warfarin revealed hemorrhage and moderate degeneration at the intervertebral tissue, as well as, column of fetus 16 day of gestation treated with high dose of warfarin appears a marked Necrosis and degeneration at the vertebrae, these similar to Li et al¹⁸. The changes in vertebra column of fetus may be

because of the role of warfarin to inhibition vitamin K regeneration by inhibiting the necessary enzyme epoxide reductase¹⁹. There is a significant decrease in the Matrix Gla protein in the serum of the pregnant rats in both treated group with low doses of warfarin and high doses of warfarin in both (16th) day gestation at level ($p < 0.05$) compared with the control group, our study agrees with Elango et al²⁰. by which the warfarin reduces gamma-carboxylation of MGP, which may be act as a central role in abnormal development of fetuses. There is a significant decrease in the osteocalcin at the level ($p < 0.05$) in the serum of treated group with low dose of warfarin and the groups of the pregnant rats treated with High dose of warfarin compared with the control group, our study agrees with Sugiyama et al²¹. This study shows the effect of Warfarin on fracture risk when the patient was giving a high warfarin dose. The effect of warfarin may block peripheral vitamin K activity, so inhibiting the γ -carboxylation of osteocalcin. The endogenous change of vitamin K1 to menaquinone-4 may be contribute to the direct effects on osteocalcin level²². There are new visions into the pathogenesis of the fetal anomalies related with the prenatal warfarin exposure, warfarin is vitamin K -antagonists prevent the recycling of vitamin K in the cell, bones, cartilages, and the developing CNS and vitamin K – dependent proteins have been recognized²³. Animal studies established an effect of warfarin on the developing of bone^{24,25}.

CONCLUSION

The results suggest the role of Warfarin on the inhibition of MGP and osteocalcin in blood and tissue.

REFERENCES

1. Eason CT, Murphy EC, Wright GRG. and Spurr EB. Assessment of risks of brodifacoum to non-target birds and mammals in New Zealand. *Ecotoxicology* 2002; 11(1): 35–48.
2. Fournier-Chambrillon C, Berny PJ, Coiffier, O, Barbedienne, P, Dasse B, Delas, G, Galineau H, Mazet A, Pouzenc P, Rosoux R and Fourni (2004).
3. Wallentin L, Yusuf S, Ezekowitz MD, Alings M, Flather M, Franzosi MG, Pais P, Dans A, Eikelboom J, Oldgren J, Pogue J, Reilly PA, Yang S, Connolly SJ. Efficacy and safety of dabigatran compared with warfarin at different levels of international normalized ratio control for stroke prevention in atrial fibrillation: An analysis of the rely trial. *The Lancet* 2010; 376 (9745), 975-983.
4. Johnson JA, Gong L, Whirl-Carrillo M, Gage BF, Scott SA, Stein CM, Anderson JL, Kimmel SE, Lee MTM, Pirmohamed M, Wadelius M, Klein TE, Altman RB. Clinical pharmacogenetics implementation consortium guidelines for cyp2c9 and vkorc1 genotypes and warfarin dosing. *Clinical Pharmacology and Therapeutics* 2011; 90 (4), 625-629.
5. Zoch ML, Clemens TL, Riddle RC. New Insights into the Biology of Osteocalcin. *Bone* 2016; 82: 42-49.
6. Hoang QQ, Sicheri F, Howard AJ, Yang DS. Bone Recognition Mechanism of Porcine Osteocalcin from Crystal Structure. *Nature* 2003; 425: 977-980.
7. Roumeliotis S, Roumeliotis A, Dounousi E, Eleftheriadis T, Liakopoulos V. Biomarkers of vascular calcification in serum. *Advances in clinical chemistry*. 2020; 98, 91-147.
8. AL-Akabi D and Kata FS. Effect of Non – alcoholic fatty liver disease on some of bone biomarker in men. *open Access Macedonian journal of medical sciences*. 2021; a(A): 924-927.
9. Sawad AA & Al-Asadi FS. Comparative Study on the Time of Appearance of Primary Ossification Centers in the Skeleton of Laboratory Mice Embryo. 2009;
10. ECHA (European Chemical Agency). "Proposal for Harmonized Classification and Labelling, FORMALDEHYDE." (2011).
11. Hussein ZM. Effect of celery seeds extract on the rat fetuses induced with diabetes mellitus 2017;
12. Al-Saeed MH, Al Saeed AH & Jori MM. Study of physiological and histological changes in rabbits induced with hepatic coccidiosis. *Journal University of Karbala*. 2017;
13. Kim Suvarna S, Christopher Layton, John D. Bancroft: Bancroft's theory and practice of histological techniques. 7th ed., Churchill Livingstone British Library Cataloguing in Publication Data. ISBN: 2013; 978-0-7020-4226-3
14. Menegola E, Broccia ML & Giavini E. Atlas of rat fetal skeleton double stained for bone and cartilage. *Teratology*, 2001; 64(3), 125-133.
15. Finkelstein Y, Chitayat D, Schechter T, Keating S, and Koren G: Mother risk rounds Warfarin embryopathy following low-dose maternal exposure. *J. Obstet. Gynaecol. Can.*, 2005; 27(7):702-6.
16. Hou J, "Fetal warfarin syndrome", *Chang Gung medical journal*, 2004; vol. 27, no. 9, pp. 691.
17. Walfisch A, & Koren G. The "warfarin window" in pregnancy: the importance of half-life. *Journal of Obstetrics and Gynecology Canada*, 2010; 32(10), 988-989.
18. Li X, Zeng Z, Yang Y, Ding W, Wang L, Xu Y & Bi W. Warfarin-related epidural hematoma: a case report. *Journal of International Medical Research*, 2022; 50(3), 03000605221082891
19. Starling LD, Sinha A, Boyd D & Furck A, "Fetal warfarin syndrome", *BMJ case reports*, vol. 2012; no. 1, pp. 1-40.
20. Elango K, Javaid A, Khetarpal BK, Ramalingam S, Kolandaivel KP, Gunasekaran K, & Ahsan C, (2021).
21. Sugiyama T, Kugimiya F, Kono S, Kim YT & Oda H. Warfarin use and fracture risk: an evidence-based mechanistic insight. *Osteoporosis International*, 2015; 26, 1231-1232.
22. Evidence of secondary poisoning of free-ranging riparian mustelids anticoagulant rodenticides in France: Implications for conservation of European mink (*Mustela lutreola*).
23. Prieto AL, Weber JL, Tracy S, Heeb MJ and Lai C: Gas6, a ligand for the receptor protein-tyrosine kinase Tyro-3, is widely expressed in the central nervous system. *Brain Res.*, 1999; 816: 646–661.
24. Howe, AM and Webster WS: The warfarin embryopathy: a rat model showing maxillofacial hypoplasia and other skeletal disturbances. *Teratology.*, 1992; 46(4): 379-90
25. Sundaram KS, Fan JH, Engelke JA, Foley AL, Suttie JW and Lev M: Vitamin K status influences brain sulfatide metabolism in young mice and rats. *J. Nutr.*, 1996; 126: 2746–2751.