



Hepatoprotective activity of novel nutraceuticals of curculigo Orchioide root extract

Lalitha Chembeti^{1,2*}, N.Harikrishnan³

¹Department of Pharmaceutical chemistry, Research scholar, faculty of pharmacy, DR.M.G.R Educational & research institute, Deemed to be university, Velappanchavadi, Chennai, Tamilnadu-600077, , India.

²Department of pharmaceutical chemistry, Narayana pharmacy college, chinthareddy palem, Nellore-524002.

³Department of pharmaceutical analysis, faculty of pharmacy, DR.M.G.R Educational & research institute, Deemed to be university, Velappanchavadi, Chennai, Tamilnadu-600077, , India

***Corresponding author:** Lalitha chembeti, dept of pharmaceutical chemistry, Narayana pharmacy college, Nellore, Email: lalithachembeti@gmail.com

Submitted: 11 January 2023; Accepted: 12 February 2023; Published: 13 March 2023

ABSTRACT

The aim of this study is to investigate hepatoprotective activity of hydroalcoholic extract of curculigo orchioide root in highly active antiretroviral administered rats. Animals were randomized and divided into five groups (I-V) of six animals in each group. Group I served as normal control and fed orally with normal saline 5ml/kg body weight daily for seven days. Group II rats as toxic control where as Group IV and V were treated with low dose and high doses with the Curculigo orchioide s respectively in controlled released formulation orally daily for seven days. Group III animals are treated with standard drug silymarin 25mg/kg(p.o) daily for seven days. On the seventh day, paracetamol suspension was given by oral route, in a dose of 750mg/kg body weight to all rats except the rats in group I. The biochemical parameters were estimated after an 18h fast following the last dose

Keywords: *Weight, Daily, Control, Activity*

INTRODUCTION

Liver is the largest organ in human body it is a metabolically active organ responsible for many vital life functions. It also plays a great role in carbohydrate, protein metabolism and fats also. It also plays a surprising role in the maintenance, performance and regulating homeostasis of the body. 15 Nutraceuticals contain health-supporting ingredients or natural components that have an ability health benefit for the body. 1 Curculigo orchioide is a small herb found in India in the sub tropical Himalayas from

Kumaon eastwards and in the western ghats from Konkan southwards. It is commonly known as kalimusli in Hindi. Its tuberous roots are used as alternative, demulcent, diuretic, restorative and for the treatment of jaundice. It is also the components of several ayurvedic tonics.³

Evaluation Of Hepatoprotective Activity

Method used in the present study (Paracetamol induced hepatotoxicity)
Hepatoprotective activity of aqueous extract of the root of Curculigo orchioide was studied using this method⁶

Paracetamol induced hepatotoxicity

Rats were divided into control, toxic, standard and test groups each comprising of 6 animals in all sets of experiments.⁷

The protocol for the study of hepatoprotective activity is shown in the table 1

Paracetamol-induced hepatotoxicity in rats

Animals were randomized and divided into five groups (I-V) of six animals in each group. Group I served as normal control and fed orally with

normal saline 5ml/kg body weight daily for seven days. Group II rats as toxic control where as Group III and IV were treated with low dose and high doses with the C.orichonoides respectively in controlled released formulation orally daily for seven days. Group V animals are treated with standard drug silymarin 25mg/kg(p.o) daily for seven days. On the seventh day, paracetamol suspension was given by oral route, in a dose of 750mg/kg body weight to all rats except the rats in group I .The biochemical parameters were estimated after an 18h fast following the lastdose⁹.

TABLE 1: Protocol for study of hepatoprotective activity of Plant CO in wistar albino rats

| Group | Treatment(1-7)days (P.O) | Toxicanton 8thday(singledose) (P.O) |
|-----------------------|---|-------------------------------------|
| Control | Normal saline 5ml/kg body weight | - |
| Toxic control | Normal saline 5ml/kg body weight | Paracetamol750mg/kg b.w |
| Standard | 0.5% silymarin 25mg/kg, (1ml/200g) | Paracetamol 750mg/kg b.w |
| Test drug (low dose) | C.orchoides Controlled release tablet 300mg/kg in Distilled water | Paracetamol 750 mg/kg b.w |
| Test drug (high dose) | C.orchoides Controlled release tablet 600mg/kg in distilled water | Paracetamol 750 mg/kg b.w |

Bio-chemical analysis

Biochemical studies

The blood was obtained from all animals by puncturing retro-orbital plexus. The blood samples were allowed to clot for 45 min at room temperature. Serum was separated by centrifugation at 2500rpm at 300C for 15 min and utilized for the estimation of various biochemical parameters namely SGOT, SGPT , serum bilirubin and total protein. After collection of blood samples the rats indifferent groups were sacrificed and their livers were excised immediately and washed in ice cold normal saline. And stored in 10% neutral buffered formalin for histopathological screening.⁹

Serum hepatospecific markers

Estimation of serum glutamic oxaloacetic transaminase (SGOT)

Activities of serum glutamate oxaloacetate transaminase (SGOT) estimated by the method of Reitman and Frankel 0.05 ml of serum with 0.25 ml of substrate (aspartate and α-ketoglutarate in

phosphate buffer pH 7.4) was incubated for an hour, 0.25 ml of DNPH solution was added to arrest the reaction and kept for 20 min in room temperature. After incubation 1 ml of 0.4N NaOH was added and absorbance was read at 505 nm in uv-vis spectrophotometer¹⁰. Activities were expressed as IU/L.

Estimation of serum glutamic oxaloacetic transaminase (SGPT)

Activities of serum glutamate oxaloacetate transaminase (SGPT) estimated by the method of Reitman and Frankel . 0.05 ml of serum with 0.25 ml of substrate (alanine and α - keto glutarate, in phosphate buffer pH 7.4)was inciubated for 30 mins 0.25 ml of DNPH solution was added to arrest the reaction and kept for 20 min in room temperature. After incubation 1 ml of 0.4N NaOH was added and absorbance was read at 505 nm in uv-vis spectrophotometer. Activities were expressed as IU/L.

Estimation of serum total bilirubin

Serum total bilirubin level was estimated based on the method of Malloy and Evelyn. Diazotised sulphonilic acid (0.25 ml) reacts with bilirubin in diluted serum (0.1 ml serum + 0.9 ml distilled water) and forms purple colored azobilirubin, which was measured at 540 nm in uv-vis spectrophotometer. Activities of total bilirubin were expressed as mg/dl.

Estimation of serum total protein

Serum total protein level was estimated based on the method of Gornall. Biuret reagent (1.0 ml) reacts with serum (10 μ L) and the colour developed was read at 578 nm in uv-vis spectrophotometer. Activities of total protein was expressed as mg/dl.

Estimation of alkaline phosphatase

Alkaline phosphatase activity was assayed using 758 Trop J Pharm Res September 2007; 6 (3) disodium phenyl phosphate as substrate. The colour developed was read at 510 nm in uv-vis spectrophotometer after 10 min. Activities of ALP was expressed as IU/L.

Principle

Transaminase is an enzyme catalyzing the transfer of amino groups from α -amino acid to α -keto acid as follows.

L-Aspartate + α -Ketoglutarate > Oxaloacetate + L-Glutamate

Oxaloacetate + NADH+H⁺ > L-Malate + NAD⁺

The rate of decrease in absorbance due to the oxidation of NADH to NAD is proportional to GOT activity. SGOT levels are 10-200 fold elevated in patients with acute hepatic necrosis, viral hepatitis, CCl₄ and drug induced poisoning. SGOT levels are also elevated by 10 fold in patients of post hepatic jaundice, intra hepatic cholestasis and less than 10 fold in alcoholic and hepatic steatosis. Very high levels are seen in extensive acute hepatic necrosis such as in severe viral hepatitis and acute cholestasis.

Reagents

Buffer: Tris buffer 88mM, PH L-Aspartate 260 mM

Enzymes:

MDH \geq 600U/L

LDH \geq 900U/L

NADH 0.2mM

α -Ketoglutarate 12mM

Test procedure

Mixed the reagents and after 1 minute incubation, measured the change in absorbance for 3minutes. Determined the mean absorbance change per minute and calculated using the formula given below.

Wavelength : 340 nm

Temperature : 37°C

GOT Activity IU/L = Δ OD/min. x 1746 (factor)

Estimation of serum glutamate pyruvate transaminase (SGPT)

ALT or SGPT is acytosolic enzyme primarily present in the liver. Its normal serum level is 10-35 Karmel units/ml.

ALT reversibly catalyses amino group from alanine to α -Ketoglutarate. L-Alanine + α -Ketoglutarate

Estimation of serum bilirubin

The serum bilirubin level is one of the best tests of liver function. Bilirubin is the metabolic product of the breakdown of haeme derived from senescent red blood cells. Each day about 7.5 g of haemoglobin is catabolized with the corresponding production of 250 mg bilirubin. Normally, 0.25 mg/dl of conjugated bilirubin is present in the blood of an adult. Bilirubin level rises in diseases of hepatocytes, obstruction to biliary excretion into duodenum, in hemolysis and defects of hepatic uptake and conjugation of bilirubin treatment such as Gilbert's disease.

Estimation of serum protein

Liver cells synthesise albumin, fibrinogen, prothrombin, alpha-1-antitrypsin, haptoglobin, ceruloplasmin, transferrin, alpha foetoproteins

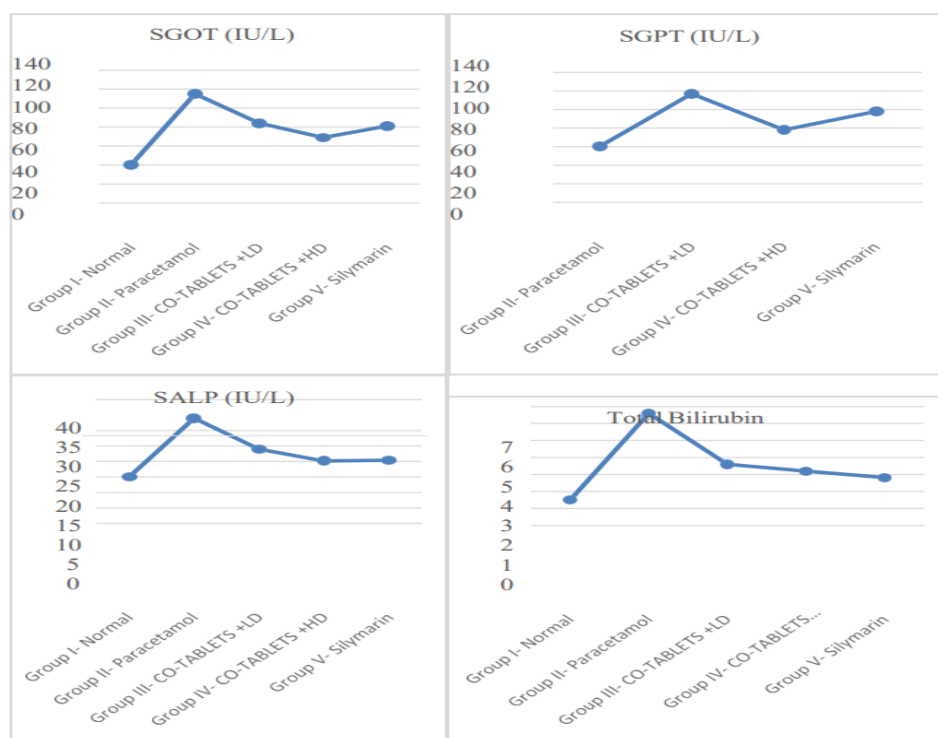and acute phase reactant proteins. The blood levels of these plasma proteins are decreased in extensive liver damage. Routinely estimated total proteins are in the normal range of 5.5 to 8 gm/dl. Hypoalbuminaemia may occur in liver diseases having significant destruction of hepatocytes. Hyperglobulinaemia may be present in chronic inflammatory disorders such as in cirrhosis and chronic hepatitis.

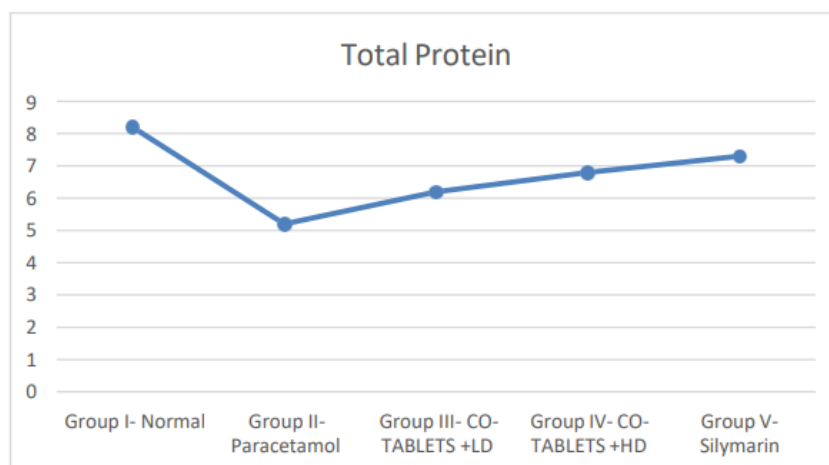
Statistical analysis

The experimental results were expressed as the Mean ± SEM for six animals in each group. The biochemical parameters were analysed statistically using one-way analysis of variance ANOVA, followed by Dunnett’s mutiple comparison test (DMCT). P value of < 0.05 was considered as statistically significant.

TABLE 2: Effect of C.orchonoides and Silymarin on serum enzymes (SGPT, SGOT and ALP),Total bilirubin and total protein on paracetamol induced liver damage in rats.

| Groups and treatment | SGOT (IU/L) | SGPT (IU/L) | SALP (IU/L) | Total Bilirubin (mg/dl) | Total Protein (mg/dl) |
|--------------------------------------|----------------|----------------|----------------|-------------------------|-----------------------|
| Group I- Normal (NaCl 0.9% w/v) | 46.17 ± 2.13 | 58.33 ± 2.31 | 17.13 ± 1.34 | 1.50 ± 0.11 | 8.01 ± 0.53 |
| Group II- Paracetamol control | 120.53 ± 1.72* | 115.00 ± 2.57* | 34.24 ± 1.96* | 6.70 ± 0.63* | 5.46 ± 0.22* |
| Group III- CO-TABLETS + Paracetamol | 83.67 ± 3.16** | 77.52 ± 1.83** | 22.88 ± 1.12** | 3.36 ± 0.15 | 6.16 ± 0.11** |
| Group IV- CO-HDTABLETS + Paracetamol | 69.17 ± 1.74** | 67.55 ± 1.58** | 19.81 ± 1.24** | 2.58 ± 0.32** | 6.93 ± 0.21** |
| Group V-Silymarin Paracetamol | 82.67 ± 2.35** | 69.33 ± 2.06** | 22.39 ± 1.89** | 2.58 ± 0.35** | 7.25 ± 0.24** |





Values are Mean \pm SEM; n = 6 animals in each group; *P<0.05 is considered significant when compared with group I; **P<0.05 is considered significant when compared with group II by Dunnett's multiple comparison test.

Assessment of liver function

Assessment of liver function was done by studying changes in biochemical parameters and histopathology.

Biochemical parameters

Serum glutamic oxaloacetate transaminase (SGOT) and Serum glutamic pyruvic transaminase (SGPT)/(ALT) were estimated by Reitman and Frankel method. Total bilirubin and total protein were also estimated.

Histopathological study

Small pieces of liver tissues in each group were collected in 10% neutral buffered formalin for proper fixation. These tissues were processed and embedded in paraffin wax. Sections of 5- 6 μ m in thickness were cut. These sections were examined photo microscopically for necrosis, steatosis and fatty changes of hepatic cells.

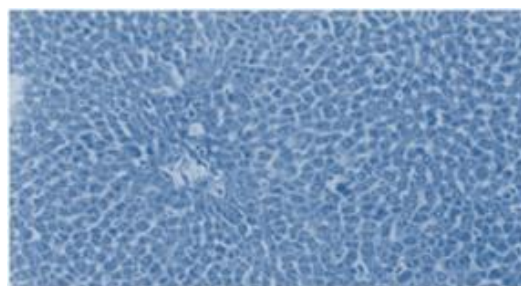


FIG 1: Photomicrograph of liver tissue of control rats showing normal hepatic cells with central vein and sinusoidal dilation 100x

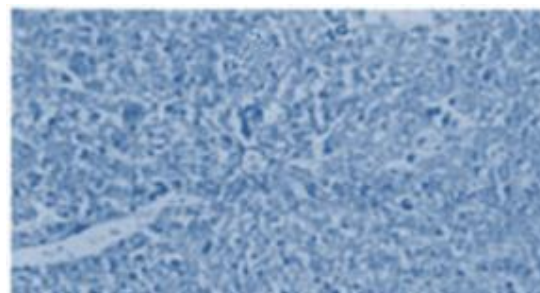


FIG 2: Photomicrograph of liver tissue of rats treated with paracetamol showing severe necrosis with disappearance of nuclei 100x

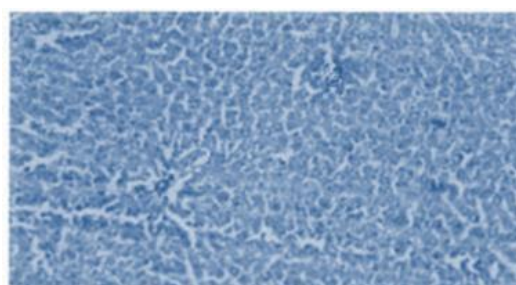


FIG 3: Photomicrograph of liver tissue of rats treated with C.O-TABLETS at 333 mg/kg showing mild degree of necrosis with normal cells (100x)




FIG 4: Photomicrograph of liver tissue of rats treated with C.O at 666mg/kg showing normal hepatocytes with mild inflammation of portal triad (100x)

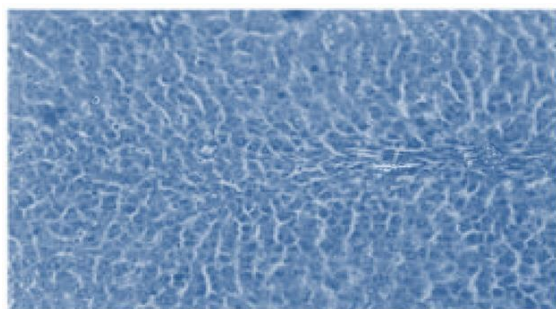


FIG 5: Photomicrograph of liver tissue treated with Silymarin at 25mg/kg showing normal hepatocytes, portal vein and portal artery (100x)

Statistical analysis

The results are expressed as Mean +S.E.M and the statistical significance of difference between groups was analyzed by one-way ANOVA followed by Dunnett's multiple comparison test. $P < 0.05$ was considered as significant.

CONCLUSION

The bio-chemical analysis of liver bio markers and the histopathological changes in liver shows that significant effect in high dose C.orchinoides control release tablet when compared with disease control and it also shows the significance reduction of hepatotoxicity comparative to the standard treated group.

Photomicrographic observations of liver images of animals treated with high dose C.O shows that significant reduction of hepatotoxicity when compared with changes of liver observed in disease control.

REFERENCES

1. Bafna AR and Mishra SH, Immunostimulatory effect of methanolic extract of Curculigo orchioides on immunosuppressed mice. *Journal of Ethnopharmacology*. 104; 2006: 1-4.
2. Anuj kumar A and Sanjaya Kumar P, Phytochemical screening of root tubers of Curculigo orchioides Gaertn. *Journal of Chemical and Pharmaceutical research*. 2(2); 2010: 107-11
3. Hari Babu B et al. Phytochemical and antimicrobial screening of Givotia rottleriformis Griff. *Journal of Pharmacy Research*. 2011: 2146-2148
4. Harborne JB. *Phytochemical Methods*, Chapman & Hall, London.1983; 3rd Ed: pp. 1-3
5. Paget GE and Barnes JM, Evaluation of drug activities, In: Laurence DR. and Bacharach AL (Eds.), *Pharmacometrics*, Academic Press, London.1983; Vol. 1: p. 115.
6. Sharada AC, et al., Toxicity of Withania somnifera root extract in rats and mice. *International Journal of Pharmacognosy*, 31(3); 1993: 205-212.
7. Rajesh SV et al., Effect of Clausen dentata (Willd.) M. Roem. against paracetamol induced hepatotoxicity in rats. *Pakistan Journal of Pharmaceutical Sciences*, 22(1); 2009: 90-91
8. Mishra SH and Sureshkumar SV, Hepatoprotective effect of Pergularia daemia (Forsk.) ethanol extract and its fraction. *Indian Journal of Experimental Biology*, 46; 2008: 447-452.
9. Biswadev B et al., Hepatoprotective and immunomodulatory properties of Tinospora cordifolia in CCl4 intoxicated mature albino rats. *Journal of Toxicological Sciences*, 27(3); 2002: 139-146.
10. Dianzani MU, Biochemical aspects of fatty liver, In: Meeks, RG, Harrison SD and Bull RJ, (Eds.). *Hepatotoxicology*, CRC Press, Boca Raton, FL.1991: pp. 327-399.
11. Clawson GA, Mechanisms of Carbon Tetrachloride Hepatotoxicity. *Pathology and Immunopathology Research*, 8(2); 1989: 104-112.
12. Sallie R et al., Drugs and the liver. *Biopharmaceutics and Drug Disposition*, 12; 1991: 251-259
13. Thabrew M and Joice PA, Comparative study of the efficacy of Pavetta indica and Osbeckia octanda in the treatment of liver dysfunction. *Planta Medica*, 53(3); 1987: 239-241.

14. Moss DW and Butterworth PJ, *Enzymology and Medicine*, Pitman Medical Co., London.1974: pp.139-141.
15. Cencic A, Chingwaru W. The role of functional food nutraceutical and food supplements in intestinal health.*Nutrients*. 2010 June; 2(6): 611–625