



# Journal of Population Therapeutics & Clinical Pharmacology

RESEARCH ARTICLE

DOI: 10.47750/jptcp.2023.30.04.005

## Dynamic Hip Screw Augmented by Trochanteric Stabilizing Plate versus Proximal Femoral Nail in Fixing Unstable intertrochanteric Femoral Fracture

Ahmed Ayman Kelany<sup>1</sup>, MBBCh; Mahmoud Mabrouk Saied<sup>2</sup>, Yaser El Sayed Hassan wahd<sup>3</sup> and Mohamed Ramadan Elfeshawy<sup>4</sup>

<sup>1</sup>Resident of Orthopedic and Traumatology, Surgery

<sup>2,3,4</sup>Department of orthopedic surgery, Faculty of medicine for girls, Al-Azhar university.

Corresponding Author: Ahmed Ayman Kelany, Resident of Orthopedic and Traumatology, Surgery

Email: ahmedelkelany1907@gmail.com, dr.mahmoudmabrouk@yahoo.com, yaserwahd@yahoo.com, mohamedelfeshawy2060@gmail.com

Submitted: 20 January 2023; Accepted: 19 February 2023; Published: 05 March 2023

### ABSTRACT

**Background:** Intertrochanteric fractures are fractures that involve the proximal region of the femur from the extra capsular part of the femoral neck to the transverse line at the level of the distal end of the lesser trochanter. **Aim:** The goal of this study was to compare the clinical outcomes of dynamic hip screw augmented by trochanteric stabilizing plate and proximal femoral nail in fixing unstable trochanteric femoral Fracture subjectively and objectively, and evaluated the results of both techniques, highlight their limitations and point out to their complications. **Patients and Methods:** This was a prospective comparative randomized study carried out at department of Orthopedics at Alzhraa University Hospital and Elmataryia Teaching Hospital. The study population comprised 30 patients with unstable trochanteric femoral fracture, attending during the study period. **Results:** There was statistically significant difference between the two studied groups as regard blood loss. Group 2 less blood lose than group 2 due to small incision, less release soft tissue and more closed reduction, and there was statistically insignificant difference between the two studied groups as regard post-operative complications. **Conclusion:** There were no significant differences between PFNA and DHS with TSP in view point of radiologic and clinical outcomes in unstable intertrochanteric fractures of the femur, but PFNA is less invasive device than DHS with TSP, therefore it may be useful device in elderly patients. **Key Words:** Dynamic Hip Screw; Trochanteric; Stabilizing Plate; Femoral Nail; Unstable intertrochanteric; Femoral Fracture

### INTRODUCTION

Intertrochanteric fractures are fractures that involve the proximal region of the femur from the extra capsular part of the femoral neck to the transverse line at the level of the distal end of the lesser trochanter<sup>(1)</sup>.

Intertrochanteric fractures account for nearly 50% of fractures around the hip. In occurs commonly in elderly with osteoporotic bone from a simple fall whereas in young individuals it results from high energy trauma. They continue to be a major cause of disability, leading to increased morbidity and mortality<sup>(2)</sup>.

An unstable pertrochanteric fracture is defined as a three part fracture with an additional posteromedial fragment that includes the lesser trochanter (31-A2.2 or 31-A2.3 according to the OTA and AO criteria), a four-part fracture with an additional fragment, including the greater trochanter, or a subtrochanteric fracture<sup>(3)</sup>.

The intertrochanteric fractures can be managed by conservative methods and the fracture usually unites but with malunion leading to various deformities, shortening, and limitation of hip movements. It is also

J Popul Ther Clin Pharmacol Vol 30(4):e34–e44; 05 March 2023.

This article is distributed under the terms of the Creative Commons Attribution-Non Commercial 4.0 International License. ©2022 Mohan R, et al.

## Dynamic Hip Screw Augmented by Trochanteric Stabilizing Plate versus Proximal Femoral Nail in Fixing Unstable Intertrochanteric Femoral Fracture

associated with significant increase in morbidity and mortality rate from prolonged immobilization like bedsores, deep vein thrombosis and co-morbid medical problems like cardiovascular, renal and respiratory<sup>(4)</sup>.

Internal fixation of the intertrochanteric fracture has become the ideal choice aiming the fractures to become stable enough to promote early mobilization preventing these complications. Currently, the methods of fixation either extramedullary fixation systems such as dynamic hip screw, dynamic condylar screw and percutaneous locked compression plate or intramedullary systems such as proximal femur nail and Gamma nail<sup>(5)</sup>.

Re-establishing a stable posterior and medial cortices and lateral wall to counteract the displacing force is the key to a successful treatment. To buffer the displacing forces and repair trochanteric fractures, additional implants have been developed. Among the variety of fixation methods, a combination of a trochanter-stabilizing plate (TSP) with a DHS and the use of intramedullary nails appear to be a promising solution for unstable intertrochanteric fractures<sup>(6)</sup>.

The goal of this study was to compare the clinical outcomes of dynamic hip screw augmented by trochanteric stabilizing plate and proximal femoral nail in fixing unstable trochanteric femoral Fracture subjectively and objectively, and evaluated the results of both techniques, highlight their limitations and point out to their complications.

### PATIENTS AND METHODS

This was a prospective comparative randomized study carried out at department of Orthopedics at Alzhrara University Hospital and Elmataryia Teaching Hospital. The study population comprised 30 patients with unstable trochanteric femoral fracture, attending during the study period.

**Inclusion criteria:** Age: 18-60 years, closed fracture, open G1, all patients who have unstable inter-trochanteric fractures, patients fit for surgery and recent fracture.

**Exclusion criteria:** Fractures extending into subtrochanteric region, reverse obliquity fractures, pathological fractures, G2 and G3 compound

fractures, active sepsis and patients not fit for surgery.

**Methods:** Written informed **consent** was obtained from all patients before beginning, after explaining the objective of the study.

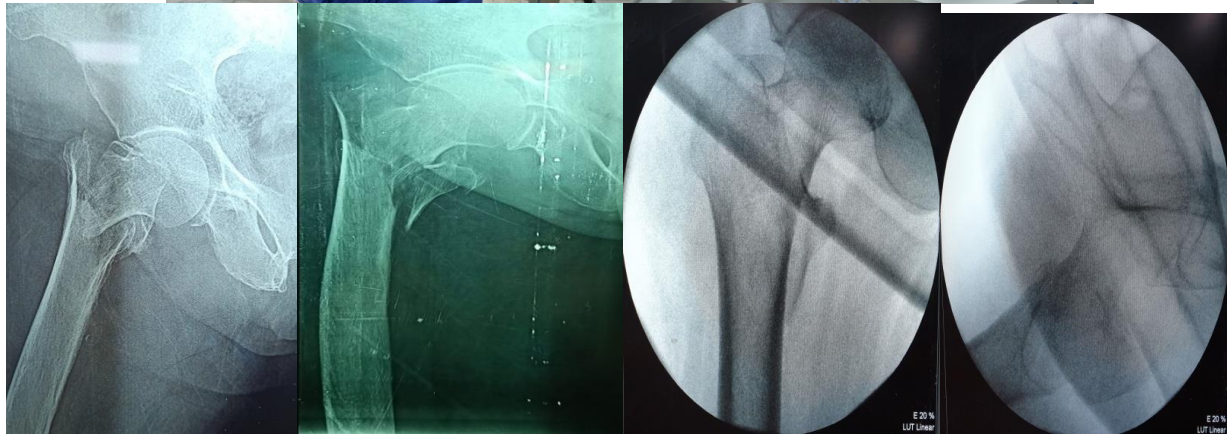
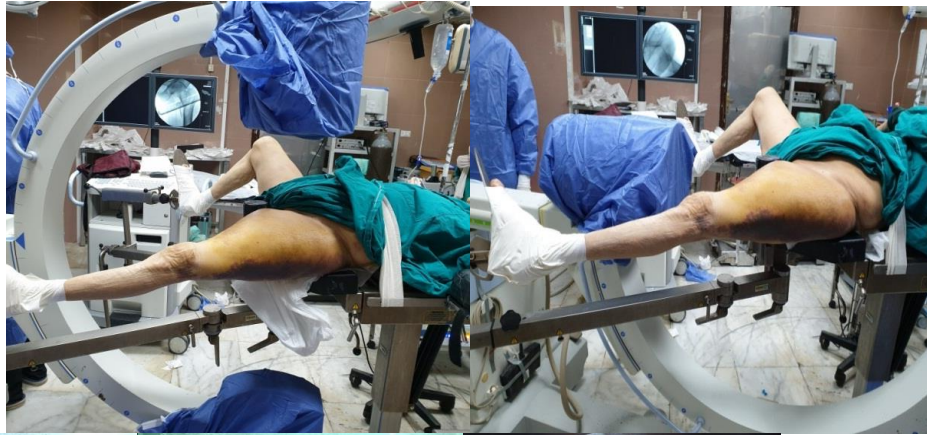**Pre-operative preparation:** Full history was taken including: name, age, sex, comorbidities as DM, HTN, cardiac or others, mechanism of injury, associated injuries, medical illness, preinjury status and previous operation. Detailed examination of the fracture limb, status of skin and soft tissue and any ecchymosis on the affected side, any associated injuries, also full neurovascular examination was done. Pre fracture level of activity and mobility. Radiological examination: Plain X-ray: anteroposterior and lateral view. CT scan: will be needed in some cases to detect the extension of the fracture. Laboratory testing: Routine preoperative CBC, coagulation profile, liver and kidney function tests. Blood glucose level when indicated.

**Surgical technique: Dynamic hip screw augmented by trochanteric stabilizing plate:**

Operation was done under regional (spinal and epidural) anesthesia; with the patient in the supine position on a traction table. Closed reduction was done under the control of an image intensifier on both views and maintained by traction. Scrubbing and sterile draping of the patient was done.

Technique for reduction and Patient positioning: Make sure patient has Foley urinary catheter in place. Patient supine with feet padded with webril and placed firmly in fracture table boots if contralateral leg dropped down, if raising contralateral leg up 90° use thigh holder. Padded post deep into groin, move genitals and Foley catheter out of the way. Prep and drape entire leg up to iliac crest to make sure adequate working area. C-arm from contralateral side at 45° towards hip. Take initial fluoro AP / Lat of hip to examine femoral neck. Mark position of C-arm to ensure proper positioning during remainder of case (~15° tilt for correct AP xray of hip. Start reduction by traction table (fine and gross traction) with internal or external rotation and abduction or adduction of the limb.

## Dynamic Hip Screw Augmented by Trochanteric Stabilizing Plate versus Proximal Femoral Nail in Fixing Unstable intertrochanteric Femoral Fracture



Skin incision and lateral approach to the hip:

**Mark and make the incision:** make straight lateral incision two finger breadths below the vastus ridge to a point 7 - 9 cm distally.

**Incise the fascia lata:** make an incision in line with the fascia lata.

**Place retractors:** place Charnley retractor deep to the IT band use blunt dissection between the vastus lateralis and the IT band to remove the adhesions

**Retract the vastus lateralis anteriorly.**

**Expose the bone:** insert 2 large Bennet retractors over the anterior edge of the femur, and rest the retractor handles underneath the previously applied Charnley retractor use a periosteal elevator to strip the remaining tissue from the lateral aspect of the femur. Determine the amount of anteversion by placing the DHS guide pin anteriorly along the femoral neck with the use of the appropriate DHS angle guide.

**Align the DHS angle guide:** align the appropriate DHS angle guide along the axis of the femoral shaft. Insert a DHS guide pin through the appropriate DHS angle guide, this should be parallel to the anteversion pin and directed toward

below the center of the femoral head (inferior position). Use image intensification to confirm the placement of the DHS guide pin under image intensification.

**Remove the anteversion pin.**

**Assemble the appropriate DHS triple reamer**

set the reamer to the correct depth, insert the DHS triple reamer into the power drive using the large quick coupling attachment, slide the reamer over the guide pin to simultaneously drill for the plate/barrel junction to the preset depth when reaming into the dense bone, continuously irrigate the DHS triple reamer to prevent thermal necrosis. Insert the lag screw by turning the handle clockwise until the 0 mark on the assembly aligns with the lateral cortex. Remove the handle. Before removing the assembly, align the handle so it is in the same plane as the femoral shaft.

**DHS plate placement:** Slide the appropriate DHS plate onto the guide shaft /lag screw.. Use the power drive in reverse with the Jacobs chuck attachment to withdraw the guide pin. Gently seat the plate with the DHS impactor.

## Dynamic Hip Screw Augmented by Trochanteric Stabilizing Plate versus Proximal Femoral Nail in Fixing Unstable intertrochanteric Femoral Fracture

The vastus ridge may be chiseled to further seat the plate on the bone

Contour the spoon Shaped end of the trochanteric stabilizing plate to fit the bone if necessary.

Positions the trochanteric stabilizing plates over the DHS ensure that trochanteric stabilizing plate is securely seated and that the oval hole allows clearance for the lag screw.

Optional insertion of the anti-rotation screw: Reinsert the 2.5 mm guide wire through the DHS lag screw, the slide the DHS parallel drill guide over the guide wire through the hole. Anti-rotation screw may be inserted superior and parallel to the DHS lag screw.

Closure of the wound: Flush out nail insertion site, lag screw, and interlocking screw sites with saline bulb irrigation, cauterize peripheral bleeding vessels.

**Proximal femoral nail:** All patients in our study were operated in lateral position under the C-Arm. A skin incision measuring 3–5 cm is made 10 cm proximal to the tip of the greater trochanter. Under image intensifier control, the bone awl was used to start the track on the tip of the greater trochanter (entry point) in anteroposterior view, and between the anterior one-third and posterior two-thirds in the lateral view, when there was difficulty in pushing the guidewire through the cortex of the greater trochanter. The ball-tipped guidewire was advanced into the distal fragment. Usually, reaming begins with a 9 mm medullary reamer. Reaming was performed in sequential steps by increments of 0.5 mm each. Adequate reaming was performed to allow for smooth nail insertion. A nail of appropriate size as determined preoperatively (according to the size of the medullary canal in the preoperative radiograph) was assembled into the insertion handle. The guidewire for the neck screw and the hip pin were inserted with the help of the aiming device. The hip pin was inserted first to prevent possible rotation of the medial fragment when inserting the neck screw. Rotation of the distal fragment was then confirmed, followed by distal locking and closure of the wound in layers.

**Immediate Postoperative management protocol:** After the operation was finished, all patients were

transmitted to the ward where the following protocol was followed: Intra venous broad spectrum antibiotic (cefotaxime third generation cephalosporine) was given to all patients. Low molecular weight heparin (40 IU enoxaparin) was given to all patients. Postoperative haemoglobin (Hb). patients started one day to three days after operation. All patients were discharged from the hospital on oral broad spectrum antibiotic for 10 days and low molecular weight heparin for 14 days.

All patients in our study were operated in lateral position under the C-Arm.

**Follow up:** Radiographic follow up (AP & lateral images) which carried out immediately post-operative and at regular intervals to determine the rate of fracture healing and detect any mechanical failure or insufficiency.

All patients were followed up in the outpatient clinic as follow: After 2 weeks the wound was examined and the sutures were removed. After 6 weeks x-ray was done and mobilization was encouraged. After 3 months x-ray was done to check the union, weight bearing ability was assessed and range of motion was examined. After 6 months x-ray was done to check union and complications, calculated to all cases and any complications were assessed and analyzed. Assessment Range of Motion.

**Administrative considerations:** An Official permission was obtained from Al Azhar University, Faculty of Medicine.

**Ethical consideration:** The study has been approved by the Ethics Committee. Informed consent was obtained from all patients after being informed about the aims and process of the study.

**Data management and Statistical Analysis:** Data entry, processing and statistical analysis was carried out using SPSS version 20 (**USA Statistical Package for the Social Sciences**). Tests of significance (Kruskal-Wallis, Wilcoxon's, Chi square, logistic regression analysis, and Spearman's correlation) were used. Data were presented and suitable analysis was done according to the type of data (parametric and non-parametric) obtained for each variable. P-values less than 0.05 (5%) was considered to be statistically significant.

**RESULTS**

**Table (1):** Socio-demographic data of studied patients

Groups Demographic data	Group 1* N=15	Group 2* N=15	T test	P value
Age (mean±SD)	55.5±4.4	51.5±10.4	Ttest= 1.031	0.110
Gender:			X <sup>2</sup> =	0.125
male	4(26.8)	7(46.3)	1.043	
Female	11(73.2)	8(53.7)		

\*Group1= DHS with T.S

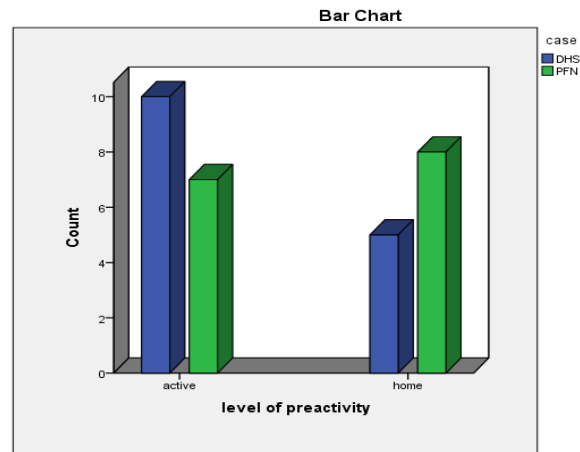
\*Group2= PFN

This table shows that there was statistically insignificant difference between the two studied groups as regard affected side of trauma.

**Table (2):** Mode of trauma in studied patients

Groups Mode of trauma	Group 1* N=15	Group 2* N=15	X <sup>2</sup>	P value
F.T.G	11(73.3)	5(33.3)	5.201	0.054
M.V.A	2(13.3)	2(13.3)		
R.T.A	2(13.3)	8(53.3)		

In group 1 there are 11 patients fall to ground (73.3%), 2 patients motor vehicle accident(13.3%) and 2 patients road traffic accident (13.3%). In group 2 there are 5 patients fall to ground (33.3%), 2 patients motor vehicle accident (13.3%) and 8 patients road traffic accident (53.5%). This table shows that there was statistically insignificant difference between the two studied groups as regard mode of trauma.



**Fig. (1):** Level of preactivity in studied patients  
There was statistically insignificant difference between the two studied groups as regard level of activity.

**Table (3):** Time till operation of studied patients

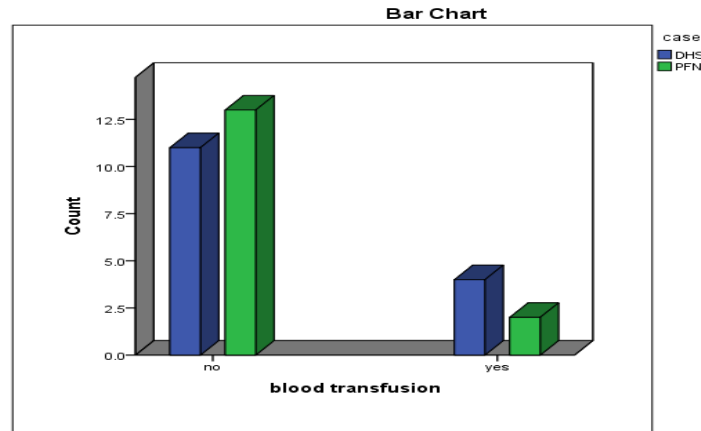
Groups Time till operation	Group 1* N=15	Group 2* N=15	T test	P value
----------------------------	---------------	---------------	--------	---------

**Dynamic Hip Screw Augmented by Trochanteric Stabilizing Plate versus Proximal Femoral Nail in Fixing Unstable intertrochanteric Femoral Fracture**

<b>Time in days (mean±SD)</b>	3.3±1.8	3.5±1.6	<b>Ttest= 2.131</b>	0.078
-------------------------------	---------	---------	---------------------	-------

There was statistically insignificant difference between the two studied groups as regard time till operation. This delay was due to many patients

were referred from other hospitals which consumed time and due co-morbidities associated with this age group.



**Fig. (2):** Blood transfusion in studied patients

There was statistically significant difference between the two studied groups as regard blood loss. Group 2 less blood lose than group 2 due to

small incision, less release soft tissue and more closed reduction.

**Table (4):** Operative time in studied patients

<b>Groups</b>	<b>Group 1*</b>	<b>Group 2*</b>	<b>T test</b>	<b>P value</b>
<b>Operative time</b>	<b>N=15</b>	<b>N=15</b>		
<b>Time in minutes (mean±SD)</b>	96.5±17.4	74.5±24.4	<b>Ttest= 2.631</b>	0.008

There was statistically significant difference between the two studied groups as regard operative

time. This is due to large incision and open and closed soft tissue that is need more time.

**Table (5):** Reduction type in studied patients

<b>Groups</b>	<b>Group 1*</b>	<b>Group 2*</b>	<b>X<sup>2</sup></b>	<b>P value</b>
<b>Reduction type</b>	<b>N=15</b>	<b>N=15</b>		
<b>closed</b>	14(93.4)	13(86.3)	2.151	0.075
<b>Open</b>	1(6.6)	2(13.7)		

In group 1, 1 case needed to open reduction while 14 cases managed by closed reduction. In group 2, 2 cases needed to open reduction while 13 cases

managed by closed reduction. This table shows that there was statistically insignificant difference between the two studied groups as regard reduction type.

**Table (6):** Post -operative complications in studied groups

<b>Groups</b>	<b>Group 1*</b>	<b>Group 2*</b>	<b>X<sup>2</sup></b>	<b>P value</b>
<b>Complication</b>	<b>N=15</b>	<b>N=15</b>		
• <b>DVT</b>	0(0)	0(0)	2.151	0.175
• <b>Infection</b>	1(6.6)	1(6.6)		

**Dynamic Hip Screw Augmented by Trochanteric Stabilizing Plate versus Proximal Femoral Nail in Fixing Unstable intertrochanteric Femoral Fracture**

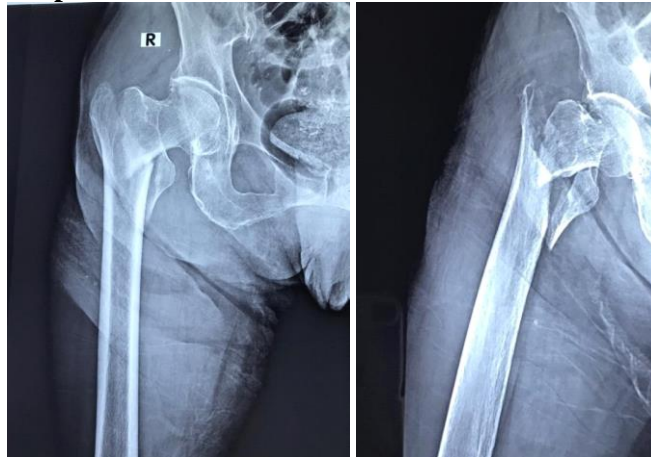
•	<b>Fixation failure</b>	1(6.6)	0(0)		
•	<b>Non-union</b>	0(0)	0(0)		
•	<b>Mal-union</b>	0(0)	0(0)		
•	<b>Medialization of lag screw</b>	0(0)	0(0)		
•	<b>Pain</b>	3(19.8)	2(13.2)		
•	<b>Abductor insufficiency</b>	0(0)	1(6.6)		
•	<b>Thigh pain</b>	0(0)	3(19.8)		

This table shows that there was statistically insignificant difference between the two studied groups as regard post-operative complications.

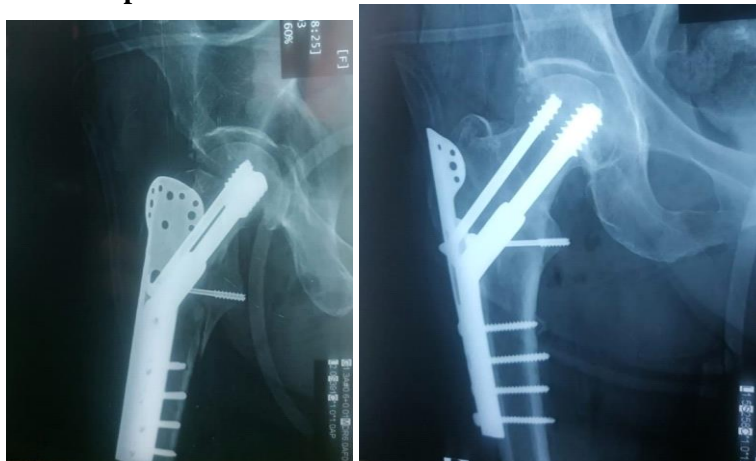Female patient 57 years old, had right unstable trochanteric fracture after falling to ground She was society active. On admission, clinical examination was done and plain x rays. She was prepared for surgery after 5 days of admission.

**Case (1)**

**Ap and Lateral views Pre-operative**

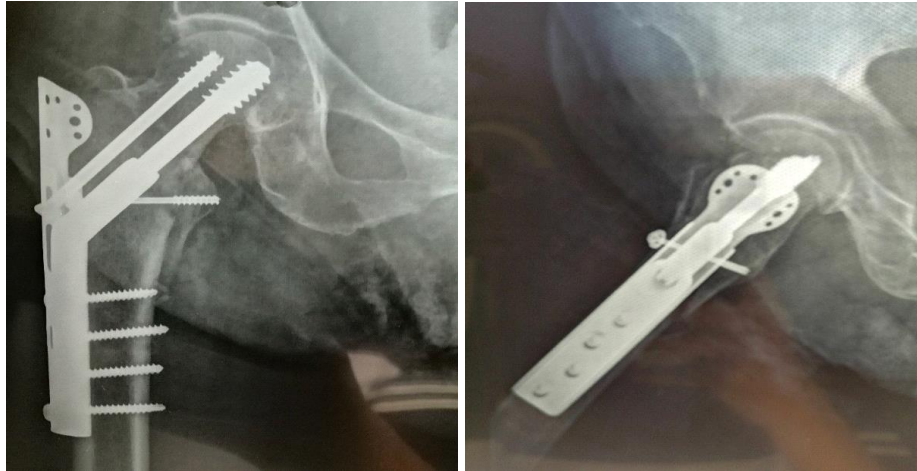


**Ap and Lateral views Post-operative**

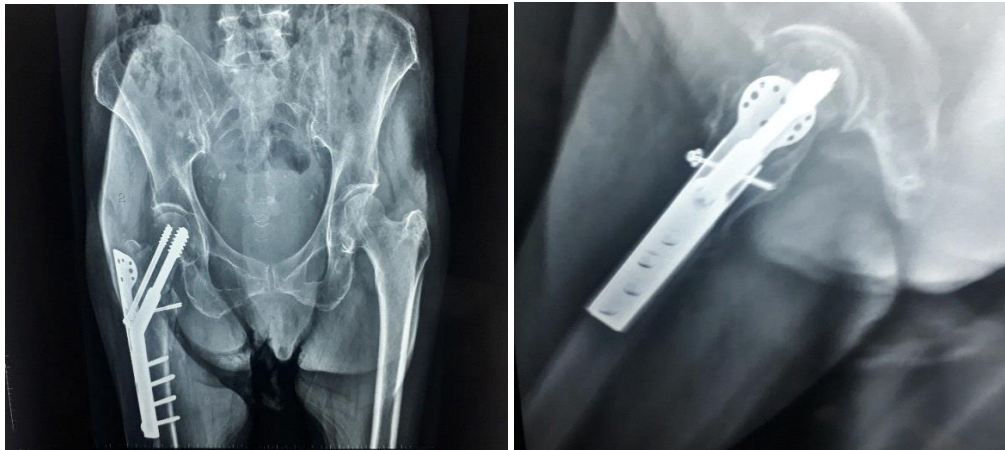


**Ap and Lateral views After 1.5 months**

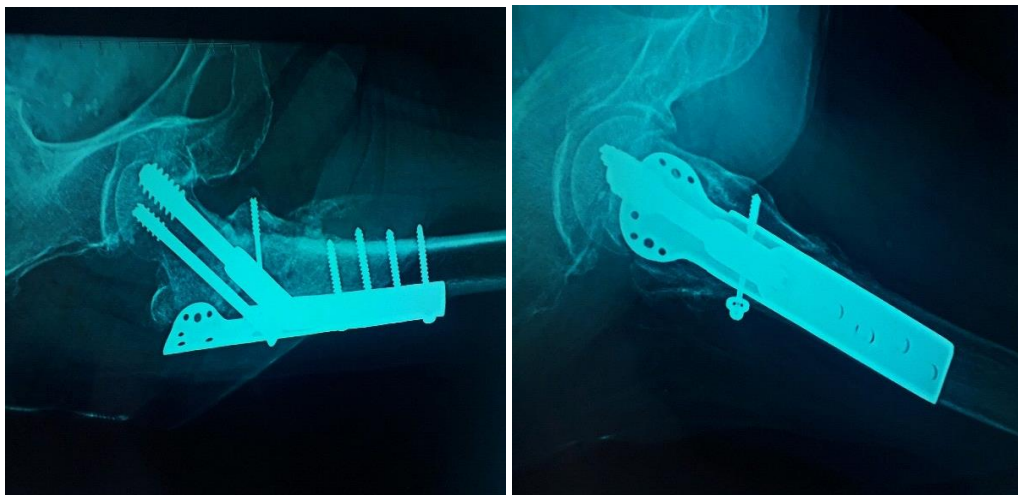
**Dynamic Hip Screw Augmented by Trochanteric Stabilizing Plate versus Proximal Femoral Nail in Fixing Unstable intertrochanteric Femoral Fracture**



**Ap and Lateral views After 3 months**



**Ap and Lateral views After 6 months**



**DISCUSSION**

Nowadays, PFN device has been used widely in the clinic and provided by different brands with

various length, diameter, neck shaft angle, and number of cephalic screws, ability to control rotation and construction materials. Even though

J J Popul Ther Clin Pharmacol Vol 30(4):e34–e44; 05 March 2023.  
This article is distributed under the terms of the Creative Commons Attribution-Non  
Commercial 4.0 International License. ©2022 Mohan R, et al.



## Dynamic Hip Screw Augmented by Trochanteric Stabilizing Plate versus Proximal Femoral Nail in Fixing Unstable intertrochanteric Femoral Fracture

PFN has more theoretical benefit than DHS, there is still ongoing controversy whether PFN is a better choice than DHS in the literature especially from clinical studies<sup>(7)</sup>.

The aim of this study was to compare the clinical outcomes of dynamic hip screw augmented by trochanteric stabilizing plate and proximal femoral nail in fixing unstable trochanteric femoral Fracture subjectively and objectively. Evaluation for the results of both techniques, highlight their limitations and point out to their complications.

In the current study we found that there was statistically insignificant difference between the two studied groups as regards age and gender.

**Kavin Kumar et al.**<sup>(8)</sup> stated that most of patients in study were in the age of >60 years of age. In dynamic hip screw augmented by trochanteric stabilizing plate (DHS with TSP) 12 male and 14 female patients. In proximal femoral nail (PFN) 13 male and 13 female patients.

**Bhakat et al.**<sup>(9)</sup> reported that maximum age was 79 years and minimum was 51 years. The average age was 67.8 years. In both groups 13 were male and 17 were female patients.

Our current findings regarding mode of trauma clearly revealed that there was statistically insignificant difference between the two studied groups.

**Kavin Kumar et al.**<sup>(8)</sup> reported that fall from standing height (trivial fall) was most common mode of injury.

**Patil et al.**<sup>(10)</sup> showed that mode of trauma was significantly more due to trivial fall (n=27) than Road Traffic Accident (n=17). 66% had left sided injury and 34% had right sided injury.

In the current study we found that there was statistically significant difference between the two studied groups regarding blood transfusion.

**Kavin Kumar et al.**<sup>(8)</sup> stated that mean blood loss in DHS with TSP 172.6ml and in PFN was 58.26 ml.

**Bhakat et al.**<sup>(9)</sup> showed that blood loss was measured by mop count and collection in suction drain. The average blood loss in the P.F.N group was 116 ml and in the DHS group was 213 ml. blood loss is less in PFN which is statistically significant, p value < 0.0001.

In the present study we found that there was statistically significant difference between the two studied groups regarding operative time.

In agreement with our results, **Kavin Kumar et al.**<sup>(8)</sup> reported that mean operating time in DHS with TSP was 88 minutes and in PFN was 62.5 minutes. There was statistically significant difference between the two studied groups in term of duration of surgery.

**Bhakat et al.**<sup>(9)</sup> illustrated that duration of surgery was more for DHS compared to PFN. The duration of surgery as calculated from the time of Implant either DHS or PFN was randomly selected by operating surgeon. All the cases included in study were operated as soon as possible. The average delay of surgery in our study was 3 days.

Our current findings regarding reduction type clearly revealed that there was statistically insignificant difference between the two studied groups.

**Xu et al.**<sup>(61)</sup> illustrated that proportion of successful closed reduction was similar in PFN(A) and DHS (PFN 98.8% and DHS 95%, respectively).

In the current study we found that the mean time required for union of fracture in group 1 was 10 and in group 2 was 8.5.

Similar results were reported by **Rho et al.**<sup>(70)</sup> who showed that there were no differences between the groups in the mean time to bone union, changes in neck-shaft angle, sliding of screw (or blade).

In the present study we found that there was statistically insignificant difference between the two studied groups as regard time required returning to pre fracture level of activity.

**Kavin Kumar et al.**<sup>(8)</sup> illustrated that all patients treated with DHS with TSP allowed to full weight bearing on an average of 13.27 weeks and patients treated with PFN were allowed full weight bearing on an average of 10.15weeks.

Our current findings regarding post-operative complications clearly revealed that there was statistically insignificant difference between the two studied groups

This was in accordance with **Rho et al.**<sup>(11)</sup> who showed that there were no differences between the groups in terms of complications, postoperative pain, and social-function score of Jensen (p>0.05). Two cases of cutting out of the blade

## Dynamic Hip Screw Augmented by Trochanteric Stabilizing Plate versus Proximal Femoral Nail in Fixing Unstable Intertrochanteric Femoral Fracture

through the femoral head were found in proximal femoral nail group. One case of cutting out of the screw, one case of the breakage of the plate, and loosening of the plate were found in compression hip screw with trochanter stabilizing plate group as complications.

**Xu et al.** <sup>(12)</sup> performed a meta-analysis that illustrated incidence of postoperative complications, including non-union of fracture, implant failure, revision of fixation failure or arthroplasty, was not significantly different between PFN and DHS. Non-union and implant failure are the common complications directly related with compromised fixation stability.

**Gupta et al.** <sup>(13)</sup> conducted a study in which 74 patient with trochanteric fractures were treated with dynamic hip screw and trochanteric stabilizing plate. There were 34 males and 40 female patients.

### CONCLUSION

Thus present study concluded that there were no significant differences between PFNA and DHS with TSP in view point of radiologic and clinical outcomes in unstable intertrochanteric fractures of the femur, but PFNA is less invasive device than DHS with TSP, therefore it may be useful device in elderly patients.

### REFERENCERS

1. Ju, J. B, Zhang, P. X, & Jiang, B. G. Hip replacement as alternative to intramedullary nail in elderly patients with unstable intertrochanteric fracture: a systematic review and meta-analysis. *Orthopaedic Surgery*, 2019; 11(5), 745-754.
2. Zhao, K, Wang, Z, Tian, S, Hou, Z, Chen, W, Zhang, Y. Incidence of and risk factors for pre-operative deep venous thrombosis in geriatric intertrochanteric fracture patients. *International Orthopaedics*, 2022; 46(2), 351-359.
3. Zhang, W, Antony Xavier, R. P, Decruz, J, Chen, Y. D, Park, D. H. Risk factors for mechanical failure of intertrochanteric fractures after fixation with proximal femoral nail antirotation (PFNA II): a study in a Southeast Asian population. *Archives of orthopaedic and trauma surgery*, 2021; 141(4), 569-575.

4. Liu, L, Sun, Y, Wang, L, Gao, Q, Li, A, Wang, J, et al. Total hip arthroplasty for intertrochanteric fracture fixation failure. *European journal of medical research*, 2019; 24(1), 1-7.
5. Min, B. W, Lee, K. J, Oh, J. K, Cho, C. H, Cho, J. W, Kim, B. S. The treatment strategies for failed fixation of intertrochanteric fractures. *Injury*, 2019; 50(7), 1339-1346.
6. Kim, J. W, Shon, H. C, Song, S. H, Lee, Y. K, Koo, K. H, Ha, Y. C. Reoperation rate, mortality and ambulatory ability after internal fixation versus hemiarthroplasty for unstable intertrochanteric fractures in elderly patients: a study on Korean Hip Fracture Registry. *Archives of Orthopaedic and Trauma Surgery*, 2020; 140(11), 1611-1618.
7. Asif, M, ur Rehman, Y, Afsar, S. S. Outcome of dynamic hip screw with trochanteric stabilizing plate in treatment of unstable intertrochanteric femoral fractures in elderly patients. *The Professional Medical Journal*, 2022; 29(01): 31-35.
8. Kavin Kumar, S. A comparative study on functional, clinical and radiological outcome of unstable intertrochanteric fractures managed by proximal femoral nailing versus dynamic hip screw with trochanteric stabilisation plate (Doctoral dissertation, Kilpauk Medical College, Chennai), 2018.
9. Bhakat, U, Bandyopadhyay, R. Comparitive study between proximal femoral nailing and dynamic hip screw in intertrochanteric fracture of femur. *Open Journal of Orthopedics*, 2013; 3(07), 291.
10. Patil, S. N, & Srinivas, P. Comparative study between proximal femoral nail and dynamic hip screw with trochanteric stabilizing plate in unstable intertrochanteric femur fractures. *Int J Res Orthop*, 2017; 10.
11. Rho, J. Y, Kim, S. B, Heo, Y. M, Cho, S. J, Chae, D. S, Lee, W. S. Proximal femoral nail antirotation versus compression hip screw with trochanter stabilizing plate for unstable intertrochanteric hip fractures. *Journal of the Korean Fracture Society*, 2010; 23(2): 161-166.
12. Xu, H, Liu, Y, Sezgin, E. A, Tarasevičius, Š, Christensen, R, Raina, D. B, Lidgren, L. Comparative effectiveness research on proximal femoral nail versus dynamic hip screw in patients with trochanteric fractures: a systematic review and meta-analysis of randomized trials. *Journal of Orthopaedic Surgery and Research*, 2022; 17(1), 1-11.
13. Biswas, S. ., Bhagyasree, V. ., & Rathod, V. N. . (2022). A CHECKLIST OF BIRDS AND DIVERSITY OF AVIAN FAUNA IN MUDASARLOVA RESERVOIR OF

**Dynamic Hip Screw Augmented by Trochanteric Stabilizing Plate versus Proximal Femoral Nail in Fixing Unstable intertrochanteric Femoral Fracture**

VISAKHAPATNAM, INDIA . *Journal Of Advanced Zoology*, 42(02), 165–175.  
<https://doi.org/10.17762/jaz.v42i02.51>

14. Faisal, H. T. ., Abid, M. K. ., & Abed, A. . (2022). Study Of Some Biochemical Parameters in Dose During Pregnancy in Goats. *Journal Of Advanced Zoology*, 43(1), 01–06.  
<https://doi.org/10.17762/jaz.v43i1.109>
15. Wankhade, L. N. . (2022). STUDY ON BUTTERFLY FAUNA OF KARANJA (GHADGE) TAHSIL OF DISTRICT WARDHA (MAHARASHTRA). *Journal Of Advanced Zoology*, 42(02), 186–193.  
<https://doi.org/10.17762/jaz.v42i02.53>
16. Gupta, R. K, Sangwan, K, Kamboj, P, Punia, S. S, Walecha, P. Unstable trochanteric fractures: the role of lateral wall reconstruction. *International orthopaedics*, 2010; 34(1), 125-129.