



## A STUDY ON FUNCTIONAL OUTCOME OF PROXIMAL FEMORAL NAIL FIXATION IN SUBTROCHANTRIC FEMUR FRACTURES

Dr. Sindhura. B<sup>1\*</sup>, Dr. Gattu Venkata Lakshmi Kavya<sup>2</sup>, Dr. JALADI SYAM PRIYA<sup>3</sup>

<sup>1\*</sup>M.S ortho, assistant professor, Guntur medical College., GUNTUR

<sup>2</sup>M.S ortho, assistant professor, Katuri medical College., GUNTUR

<sup>3</sup>M.S ortho, assistant professor, Katuri medical College., GUNTUR

### Abstract

**Introduction:** Subtrochanteric fractures are devastating injuries that most commonly affect the elderly and also in young. Surgical management of these fractures and the surgical implants used have also gone through an array of changes in their procedures and designs. Various upper femoral devices like dynamic condylar screw, dynamic hip screw with barrel plate, gamma nail, proximal femoral nail etc are being used and reasonably satisfactory results with each type of device.

**Aim and objectives:** To study and evaluate the final outcome of management and complications of sub trochanteric fractures with proximal femoral nailing fixation.

**Methods:** In our prospective study 25 patients above the age of 18 years with subtrochanteric fractures were seen from September 2021 and November 2023 in government general hospital, Guntur. All the patients were treated with proximal femoral nail and followed up in GGH, GUNTUR in the department of orthopaedics and the functional outcome was assessed. Results of the study were compared and analyzed with other studies.

**Results:** Subtrochanteric fractures of the femur have peculiar anatomic and mechanical characteristics which poses problems in their management. Closed intramedullary devices have a mechanical advantage that effectively addresses these factors. The benefit of minimal surgical exposure, more efficient load transfer through calcar femoral and decreased tensile strain on the implant because of its shorter lever arm makes proximal Femoral Nail a good choice of implant for subtrochanteric fractures of the femur.

**Keywords:** Sub trochanteric fracture, Proximal femoral nailing.

### Introduction

Subtrochanteric fractures are the most frequent fractures of the proximal femur and occur predominantly in geriatric patients and young people. Most proximal femoral fractures occur in elderly individuals as a result of only moderate or minimal trauma. In younger patients these fractures usually result from high energy trauma. The incidence of subtrochanteric fractures is more in the male population compared to the females. Among the femoral shaft injuries upper femoral fractures present a peculiar problem of securing effective neutralization of deforming forces.

The mechanical stresses at this level are very high, as they occur at the junction between the trabecular and cortical zone and also because of the deforming forces due to peculiar muscle insertion to the proximal and distal fragments. These factors made subtrochanteric fractures defective union lead to high disability levels for an individual. Surgical management have gone through an array of changes in their procedures and designs. Various upper femoral devices like dynamic condylar screw, dynamic

hip screw with barrel plate, gamma nail, proximal femoral nail etc are being used by various centers and claims reasonably satisfactory results with each type of device <sup>[1]</sup>

### **Aims & objectives**

1. To evaluate the final outcome of management of sub trochanteric fractures with proximal femoral nailing fixation.
2. To study the usage of internal fixation by proximal femoral nailing in the treatment of subtrochanteric fractures of femur.
3. To assess the functional outcome of patients with reference to rate of fractured union and range of movements at hip and knee joints and to study the restoration of the function of the limbs.
4. To study the complications of internal fixations by proximal femoral nailing.

### **Materials and methods Study design**

Our prospective study was conducted at the hospital to evaluate the final outcome of management of sub trochanteric fractures with proximal femoral nailing fixation.

### **Study period, place of study and duration**

The study was conducted in the Government general hospital, Guntur from September 2021 to November 2023

### **Sample size**

The sample size has been estimated to 25 patients with subtrochanteric fracture admitted in our institute.

### **Inclusion criteria**

1. Sub trochanteric fractures in adults
2. Age between 20 and 60 yrs.

### **Exclusion criteria**

1. Pediatric subtrochanteric fractures
2. Patients having segmental fractures of the same bone
3. Pathological fractures
4. Old neglected fractures fractures with implant failures and compound fractures
5. Age less than 20 and more than 60yrs

### **Surgical Technique**

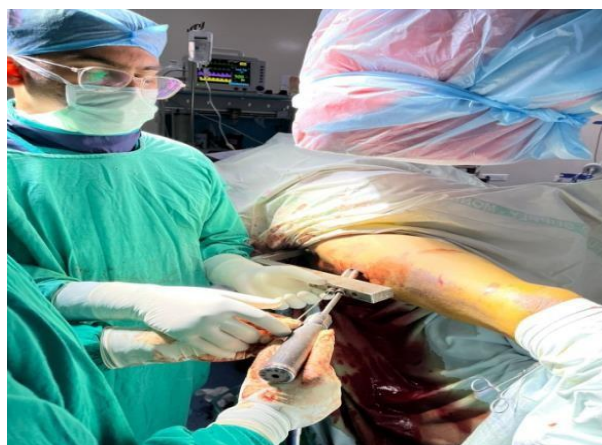With the patient in supine on fracture table, closed reduction of fracture is performed. Reduction is achieved by aligning distal fragment to flex and externally rotated proximal fragment by rotating the foot of effected extremity. A curved lateral incision is made from the level of trochanter proximally for about 6 to 9cm. Under fluoroscopic guidance, a 3.2mm pin is inserted into the tip of greater trochanter, taking care to center it on both antero posterior and lateral views. The pin is then driven 5cm into proximal femur.

An alternative to this method is to use an awl, under fluoroscopic guidance to provide the opening. The awl should be inserted up to the point of largest outer diameter under fluoroscopic guidance and then removed. A guide wire is then inserted into proximal fragment and into distal fragment. Using 9mm end cutting reamer both the fragments are reamed.

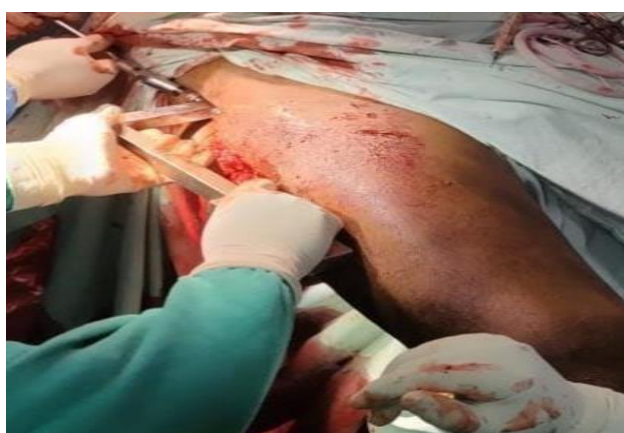The reaming process is continued at 0.5 mm increments until 1mm more than the selected nail size is reached and the proximal fragment entry point is widened with entry point widener. The selected nail is then assembled to jig and passed over the guide wire and pushed manually by rocking movements and the terminal position is hammered to the desired level and anteversion is adjusted by comparing with opposite hip or setting the anteversion of 15°.

Drill sleeves are inserted in proximal and distal holes and guide pin is inserted. Using drill bit, drill the holes over guide pin for screws insertion. The distal screw hole is drilled with 6.4 mm drill up to 5mm of subchondral bone. The length of screw to be inserted is read from calibrations on drill bit and it is tapped up to 5mm of subchondral bone and tapped with 8.0 mm tap and appropriate 8.0 mm screw is selected and inserted into the inferior hole of the nail. Now proximal screw site is drilled with 5.0 mm drill bit and tapped with cortical tap of 6.4 mm and the screw is inserted. Then the distal interlocking screw is inserted through the insertion handle.

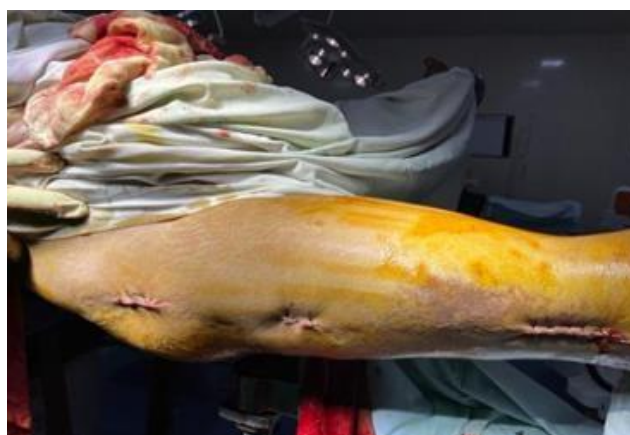This is checked on fluoroscopy in both anteroposterior and lateral views and appropriately sized screw is selected and inserted. Then the second interlocking screw is also inserted in the same manner.



**Figure 1**



**Figure 2**



**Figure 3**

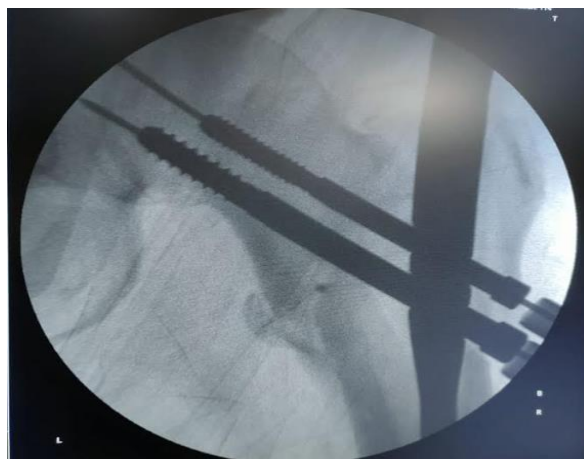

Figure 4

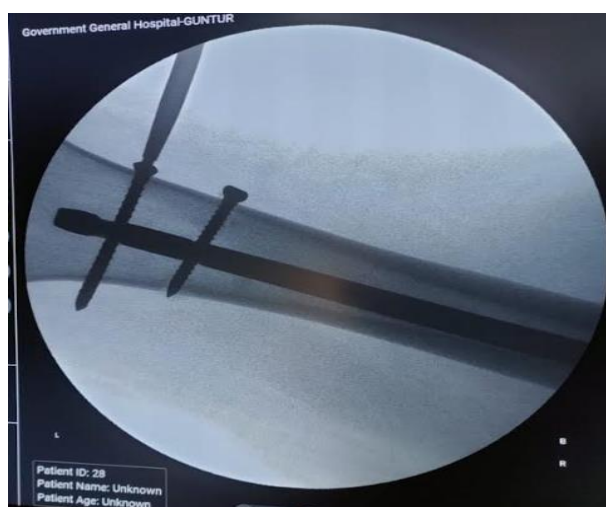



Figure 5

### Post op period and evaluation

Patients were discharged on the tenth post op day following sutures removal, of their post op period was uneventful. Patients were assessed clinically and radiologically at 2 weeks, 6 weeks, 6 months, 12 months, and at 18 months depending upon the fracture union. These findings are documented according to a protocol that was developed. Healing was judged by both clinical (pain & motion at fracture site) and radiological (bridging callus filling the fracture site or trabeculations across the fracture site) criteria and functional outcome was reviewed according to the Harris Hip score (modified).



## Results

### Age of the patient with subtrochanteric fractures

AGE GROUP (YRS)	NUMBER OF PATIENTS	PERCENTAGE
20-30	5	20%
31-45	9	36%
46-60	11	44%
TOTAL	25	100%

The youngest patient in our series is 20 years old and the oldest is 60 years. Maximum number of patients in this study is of elderly age group and the mean age is 40 years

### Sex distribution

SEX	NUMBER OF PATIENTS	PERCENTAGE
MALE	19	76%
FEMALE	6	24%
TOTAL	25	100%

In the present study, it is seen that subtrochanteric fractures are slightly more common in males than females.

### Result

	EXCELLENT	GOOD	POOR
PERCENTAGE	80%	16%	4%

Reduction was good in 80% (20) of the cases. Poor reduction was noted in 4% (1 patient).

### Complications

COMPLICATION	PERCENTAGE
SUPERFICIAL INFECTION	8%
DEEP INFECTION	0%
CUT OUT OF SCREW	4%
REVERSE 'Z' EFFECT OF HIP SCREWS	8%
'Z' EFFECT OF HIP SCREWS	0%
SHAFT FRACTURE	0%

In the present series, 8% (2) of cases had superficial infection and no deep infections were recorded. Cut of the autorotational screw was noted in 4% (1) patient. Reverse Z effect hip screws was noted 8% (2) of patients.

### Discussion

Of the long bone fractures Subtrochanteric fractures of the femur have peculiar anatomic and mechanical characteristics which poses problems in their management. Closed intramedullary devices have a mechanical advantage that effectively addresses these factors.

The benefit of minimal surgical exposure, more efficient load transfer through calcar femorale and decreased tensile strain on the implant because of its shorter lever arm makes proximal Femoral Nail a good choice of implant for subtrochanteric fractures of the femur. Various studies have considered Proximal Femoral Nail as an acceptable minimally invasive implant for Subtrochanteric fracture.

The incidence of subtrochanteric fracture is relatively low. In our study 25 subtrochanteric fractures accounted for 11% of all proximal femoral fractures. In other studies 7% - 34% of all femur fractures

occurred in the subtrochanteric region [2],[3]. Most of our patients were of the elderly age group, the average age being 40 years. This is significantly lower compared to that quoted by other authors in literature, BOLDIN ET AL [4] 73 yrs, I.B. SCHIPPER SERIES 82.2 years.

Female preponderance of 24% was noted in our patients and it was lower as compared by BOLDIN ET AL (70%) and I.B. SCHIPPER (82%). In 57.14% of patients fracture is a result of trivial fall and majority of them are elderly age group patients especially females. High velocity injuries like road traffic accidents and fall from heights accounted for 42.85% of these fractures. Similar modes of injury was reported by WEISS & BRIEN ET AL [5] 77% Associated medical problems were present in 25% of cases. In our study right sided fractures 60% were common than left side this distribution is similar to that reported by FRENCH AND TORNETTA ET AL [6]60%

The result of the reduction was considered Excellent in 80% (20) of the patients and Good in 16% (4) of patients. Poor reduction was noted in 4% (1) of patients and it was associated with poor outcome. In I.B. SCHIPPER's series 40 reduction was good to acceptable in 96.2% of their patients and poor reduction was seen only in 2.9% of their patients. Post operatively 1 patient in this study had superficial infection (4.76%) and this settled with parenteral antibiotics. I.B. Schipper noted 4.1% superficial infections and 2.5% deep infections. We did not encounter any deep infections in our series. Cut out of hip screw was noted in 1 patient (4.76%) and it was following a fall in the post op period. 6% of patients in I.B. SCHIPPER's series had this problem. 0 patient had fracture shaft of femur with breakage of the nail noted I.B. Schipper noted this problem in 2% of his patients. The average time for radiological union was 3 months in the present study whereas in I.B. Schipper series it was approximately 4 months.

Final outcome was excellent in 80% (20) of patients. It was good in 16% (4) of patients and poor in 4% (1) of patients. Younger age group patients irrespective of their fracture pattern had excellent outcome in our series. Most of the poor results were seen in the elderly age group patients with associated Osteoarthritis of the knee. The mean Harris Hip score was in our series was 78.25% which was closer to I.B. Schipper series 34 where the mean was 77.6.

The average follow up period was 10.2 months. 20 out of 25 patients had excellent result. 10 out of these patients had type III fielding's. These patients had sound union both clinically and radiologically within 3 months. None of these patients had varus deformity or shortening. The excellent recovery made by these patients is probably because of anatomical reduction and axial and rotational stability provided by Proximal Femoral Nail.

## Conclusion

The incidence of Subtrochanteric fractures of the femur is increased because of fast and high velocity automobiles and modern lifestyles and increased life expectancy of the elderly age group patients. The deforming forces, high mechanical stresses and morbidity of the fractures in this region have always challenged the ingenuity and skills of the orthopedic surgeon. Various devices have evolved in an attempt to effectively neutralize these forces. Closed insertion technique, shorter lever arm decreasing the tensile strain on the implant and increased purchase of the proximal fragment are the added advantages of Cephalomedullary nails over other fixation devices in subtrochanteric fractures. This study was conducted to analyze the results of Subtrochanteric fractures treated with this Proximal Femoral Nail

From this sample study, we conclude that Proximal Femoral Nail is a good implant for the treatment of Sub trochanteric fractures of femur provided optimal reduction of the fracture and good positioning of the nail and screws are achieved.

## References

1. Sarmiento, Augusto: Functional Bracing of Tibial and Femoral shaft Fractures. Clin Orthop. 1972; 82: 2 – 13.
2. Velasco RU, Comfort T. Analysis of treatment problems in Subtrochanteric fractures of the femur. ; J of Trauma 1978; 18: 513 – 522.

3. W.M. Gadegone, Y.S. Salphale. Proximal femoral nail – An analysis of 100 cases of Proximal femoral fractures with an average follow up of 1 Year. International Orthopedics 2007; 31: 403 – 408.
4. Boldin et al; Acta orthop scand.2003;74 (1); 53-58
5. Donald A Wiss, M.D, William W Brien M.D CORR 1992,283,232-23
6. Bruce G, French, M.D Paul Tornetta, III M.D CORR 348,1998;95-100.